


H. H. SMITH M. D.

ANATOMICAL

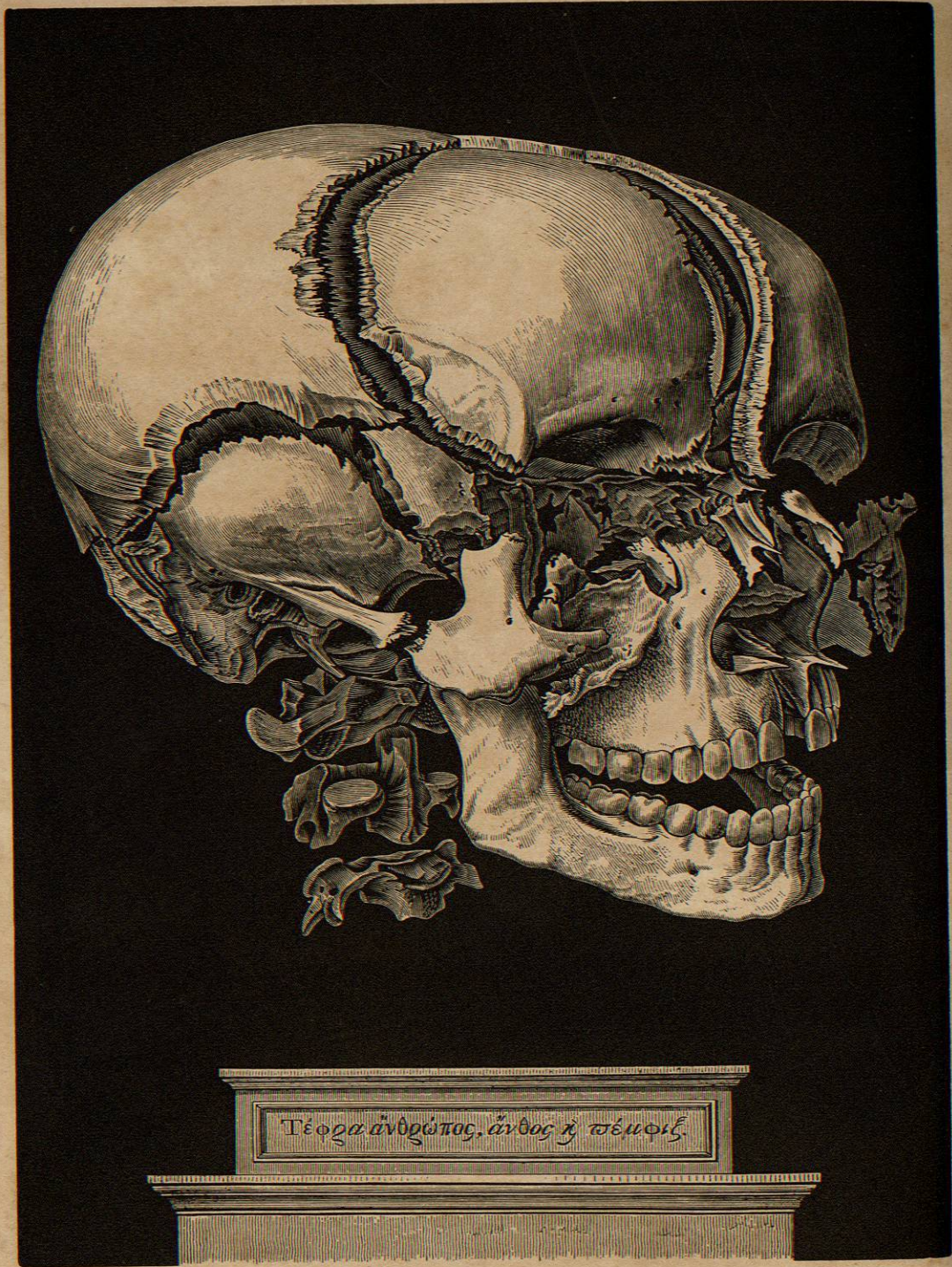
ATLAS

QM25
S65

ANATOMICAL



PLATES.



ANATOMICAL ATLAS,

ILLUSTRATIVE OF
 THE STRUCTURE
 OF
 THE HUMAN BODY.



BY
 J. B. SPENCER, M.D.
 Surgeon of the Hospital of St. George, London.
 UNDER THE SUPERVISION OF
 W. H. C. SPENCER, M.D.
 Professor of Anatomy in the University of London.

LONDON:
 LEITCH AND ANCHARD,
 1827.



000340

ANATOMICAL ATLAS,

ILLUSTRATIVE OF

THE STRUCTURE

OF

THE HUMAN BODY.



BY

HENRY H. SMITH, M.D.

Fellow of the College of Physicians, Member of the Philadelphia Medical Society, &c.

UNDER THE SUPERVISION OF

WILLIAM E. HORNER, M.D.,

Professor of Anatomy in the University of Pennsylvania &c

PHILADELPHIA:

LEA AND BLANCHARD.

1844

108.
Dr. Bantam



BIBLIOTECA

000546

QM 25
565

Entered, according to the Act of Congress, in the year 1843, by LEA AND BLANCHARD, in the clerk's office
of the district court of the United States, for the eastern district of Pennsylvania.

C. SHERMAN, PRINTER,
19 St. James St.

PREFACE.

IN the performance of the duty which has been confided to me, of forming a set of Plates as an accompaniment to the text of the work entitled, "Special Anatomy and Histology, by Wm. E. Horner, M.D., Professor of Anatomy in the University of Pennsylvania, Philadelphia, 1843," the present volume is now offered. The utility of drawings in illustration of a purely demonstrative branch, is now too well established to require any argument in its favour. Separated from the centre of instruction, and deprived of the advantages of the Dissecting Room, the ideas once so thoroughly acquired soon begin to fade, and the images once so distinct, become confused and mixed. A recourse to plates, in the absence of dead bodies, is then the only means of refreshing our knowledge.

Numerous works, framed with these intentions, have long enjoyed a large share of professional approbation; some from the finished style of their execution; others from some striking feature of simplicity, or adaptation to the wants of medical men.

The claim of the present one is, to have been selected from the most accurate of these, as well as from the latest Microscopical Observations on the Anatomy of the Tissues; and where plates were not deemed satisfactory, to have been enriched by original drawings, from specimens furnished by the beautiful Anatomical Museum of the University of Pennsylvania.

In the arrangement of the work, it will be seen that reference has been had to the production of a volume suited to general circulation, of such a size as could be conveniently used in the Lecture, Dissecting, or Operating Room; with a Terminology sanctioned by general usage in the United States, and with concomitant references on the same page, thereby saving to the young student much embarrassment and confusion. Lastly, it has been placed at such a price as will render it easy of acquirement by all.

To the attention bestowed on the plates by the artists employed in their execution, is due much of their fidelity. The original drawings, as well as those which are copies in a reduced form, are from the pencil of Mr. Pinkerton, a gentleman now most favourably known in this department of Anatomy. To say that the engravings are in Mr. Gilbert's best style, is sufficient guarantee for their beauty, his name being now identified with some of the finest wood engravings made in this country.

October, 1843.

HENRY H. SMITH,
117 South Ninth Street.

NOTICE.

OWING to other engagements of Mr. Pinkerton, the drawings for Parts Third and Fifth of this work, have been prepared by Mr. J. T. French, and those of Part Fourth by Mr. M. S. Weaver, to whose skill and experience in this department of drawing we are much indebted for the taste and correctness shown in their execution.

August, 1844.

INDEX
TO
THE ILLUSTRATIONS,

EMBRACING

SIX HUNDRED AND THIRTY-SIX FIGURES.

A HIGHLY FINISHED VIEW OF THE BONES OF THE HEAD facing the title-page.
VIEW OF CUVIER'S ANATOMICAL THEATRE vignette.

PART I

BONES AND LIGAMENTS.

Fig.	Page	Fig.	Page
1. Front View of Adult Skeleton	17	36. The First Rib	30
2. Back View of Adult Skeleton	18	37. General Characters of a Rib	30
3. Fœtal Skeleton	19	38. Front View of the Sternum	30
4. Cellular Structure of Femur	20	39. Head of a Peruvian Indian	31
5. Cellular and Compact Structure of Tibia	20	40. Head of a Choctaw Indian	31
6. Fibres of Compact Matter of Bone	20	41. Front View of the Os Frontis	31
7. Concentric Lamellæ of Bone	20	42. Under Surface of the Os Frontis	31
8. Compact Matter under the Microscope	21	43. Internal Surface of the Os Frontis	32
9. Haversian Canals and Lacunæ of Bone	21	44. External Surface of the Parietal Bone	32
10. Vessels of Compact Matter	21	45. Internal Surface of the Parietal Bone	32
11. Minute Structure of Bones	21	46. External Surface of the Os Occipitis	33
12. Ossification in Cartilage	22	47. Internal Surface of the Os Occipitis	33
13. Ossification in the Scapula	22	48. External Surface of the Temporal Bone	33
14. Puncta Ossificationis in Femur	22	49. Internal Surface of the Temporal Bone	33
15. Side View of the Spinal Column	23	50. Internal Surface of the Sphenoid Bone	34
16. Epiphyses and Diaphysis of Bone	23	51. Anterior and Inf. Surface of the Sphenoid Bone	34
17. External Periosteum	23	52. Posterior Surface of the Ethmoid	34
18. Punctum Ossificationis in the Head	24	53. Front View of the Bones of the Face	35
19. A Cervical Vertebra	24	54. Outside of the Upper Maxilla	35
20. The Atlas	24	55. Inside of the Upper Maxilla	35
21. The Dentata	24	56. Posterior Surface of the Palate Bone	36
22. Side View of the Cervical Vertebrae	25	57. The Nasal Bones	36
23. Side View of the Dorsal Vertebrae	25	58. The Os Unguis	36
24. A Dorsal Vertebra	25	59. Inferior Spongy Bone	36
25. Side View of the Lumbar Vertebrae	26	60. Right Malar Bone	36
26. Side View of one of the Lumbar Vertebrae	26	61. The Vomer	37
27. Perpendicular View of the Lumbar Vertebrae	26	62. Inferior Maxillary Bone	37
28. Anterior of Sacrum	27	63. Sutures of the Vault of the Cranium	37
29. Posterior View of Sacrum	27	64. Sutures of the Posterior of the Cranium	37
30. The Bones of the Coccyx	27	65. Diploe of the Cranium	38
31. Outside View of the Innominatum	28	66. Inside of the Base of the Cranium	38
32. Inside View of the Innominatum	28	67. Outside of the Base of the Cranium	38
33. Anterior View of the Male Pelvis	29	68. The Facial Angle	39
34. Anterior View of the Female Pelvis	29	69. The Fontanels	39
35. Front of the Thorax	30	70. The Os Hyoides	39