

THESE
MORIS
COURT

[Small white label with illegible text]

PHYSICAL
DIAGNOSIS

—
CABOT

THIRD
REVISED EDITION

RC76
C3

WM. WOOD & CO.



BIBLIOTECA



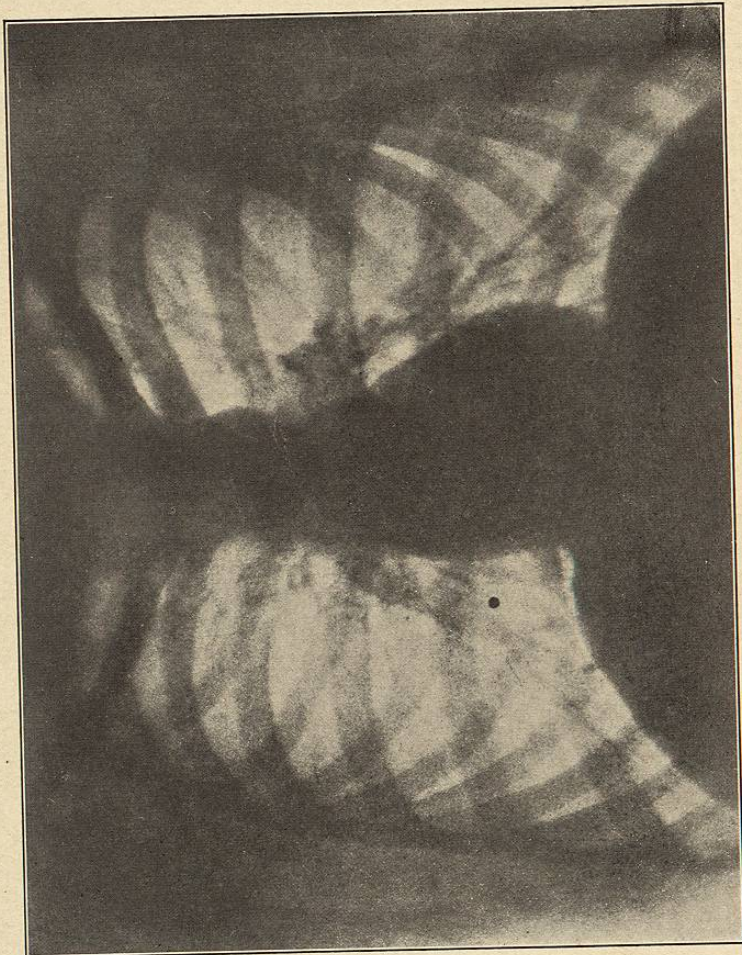
BIBLIOTECA



BIBLIOTECA



BIBLIOTECA



Instantaneous Radiograph of a Normal Adult Thorax. A dot marks the position of the right nipple. The branchings of the larger bronchi are visible.
(From v. Ziemssen's Atlas.)

PHYSICAL DIAGNOSIS

BY

RICHARD C. CABOT, M.D.

INSTRUCTOR IN MEDICINE IN HARVARD UNIVERSITY

Third Edition, Revised and Enlarged

WITH FIVE PLATES, AND TWO HUNDRED AND FORTY FIGURES
IN THE TEXT



NEW YORK
WILLIAM WOOD AND COMPANY
MDCCCCV

BIBLIOTECA

FMBSH
NO 76
C3

COPYRIGHT, 1905,
By WILLIAM WOOD AND COMPANY.

TO
FREDERICK C. SHATTUCK, M.D.

*Jackson Professor of Clinical Medicine
in Harvard University*

IN EVIDENCE OF MY APPRECIATION OF
THE EXAMPLE OF SINCERITY, COMMON SENSE, AND ENTHUSIASM
ESTABLISHED BY HIM IN THE TEACHING AND
THE PRACTICE OF MEDICINE