SECTION IV.

THE CERVIX UTERI SHOULD BE OF PROPER SIZE, FORM, AND DENSITY.

SECTION IV.

THE CERVIX UTERI SHOULD BE OF PROPER SIZE, FORM, AND DENSITY.

Of 250 married women who had never borne children, the condition of the cervix was particularly noticed in 218, the remaining 32 being excluded on account of other complications, that would mar or counterbalance any influence that the peculiarities of the cervix might exercise over the sterile condition. Of these 218—

The cervix was . . .	Flexed	in 19	71
	" and conical	" 31	
	" " and indurated	" 21	
	Straight, conical, and indurated	in 4	147
	" " " and elongated .	" 109	
	" " elongated, but not indurated .	" 7	
	" not conical, but hypertrophied and indurated	" 14	
	Granular	" 10	
	" and conical	" 3	
			218

Now of this number we find—

71 flexed,	of which 52	had a conical	cervix
147 straight,	" 123	"	"
218	175		

Thus we have a conoid cervix in nearly 85 per cent. of all cases of natural sterility.

This shows very plainly the great influence that this

peculiar abnormal form of the cervix exerts over the sterile condition; and when we remember the fact that it is almost always associated with a contracted os, we are constrained to acknowledge its importance.

Having said that the cervix should be of proper size, form, and density, let us consider its variations in size from a normal standard.

It is normally about half the length of the uterus, and projects into the vagina from a fourth to the third of an inch anteriorly, and a fraction more posteriorly. The intra-vaginal portion is rounded, truncated, and elastic to the touch; but it may vary from this in many particulars. It may be hypertrophied or elongated, or it may not project into the vagina at all. It may be flexed, indurated, engorged, or granular; but in the sterile, as shown in the table above, it is most frequently of conical form, whether straight or flexed; and with the indurated conoid form there is, as before said, almost invariably associated a contracted os.

But, independently of its mere form, if the cervix projects into the vagina a full half-inch, it is very likely to be associated with the sterile state; if an inch, the case is almost necessarily sterile; if it should be still more elongated, say one and a half or two inches, it becomes absolutely so; and if it does not project into the vagina at all, it is equally sterile.

Elongation of the cervix is very common, while its defective development is comparatively rare. This elongation is sometimes real and sometimes only apparent. It is real when the cavity of the uterus is more than two inches and a half deep, and the additional depth is seen to be due to the unnaturally developed cervix. It is only apparently too long when the depth of the cavity is normal and yet the cervix evidently

projects too far into the vagina, in consequence of the vagina being inserted too high on the cervix. But whether really or apparently too long, the same treatment is necessary. If the elongated cervix is more than an inch, the body of the uterus will almost of necessity be thrown backwards, because the neck projecting so far into the vagina, can only accommodate itself to the opposite wall, by taking the direction of its axis. This position of the cervix must be attended with a retroversion of the body, or if this be in a normal position, then, as a rule, the cervix must be flexed anteriorly. Sometimes it may result in complete procidentia, but we have only now to deal with the fact, and not its consequences.

Suppose we find the cervix too long, what are we to do with it? Some of our best authorities tell us to melt it down with the potassa c. calce or potassa fusa when it is greatly hypertrophied. I never tried to do this, but I have seen cases of hypertrophy after they were subjected to the process, and I have no hesitation in saying that it is not the safest, easiest, and best thing to be done. What is better then? Amputation; and for this there are two methods—the knife and the écraseur, the former of which I here greatly prefer. The objection to the écraseur is that it makes a lacerated surface to heal by granulation, which takes a long time, often leaving the os tincæ contracted. Another objection to it is the uncertainty of amputating just where we place the chain, which often draws in more tissue than we intend, and removes more than we wish. So great has been this trouble, that some of the German surgeons have given up the écraseur altogether in operations on the neck of the womb, because the attachment of the bladder and, in some instances, the posterior cul-de-sac of the vagina,

have been injured, and even the peritoneal cavity opened by its greedy grasp. It might be supposed that these accidents are hypothetical, but unfortunately I can testify personally to the truth of, at least, one of them.

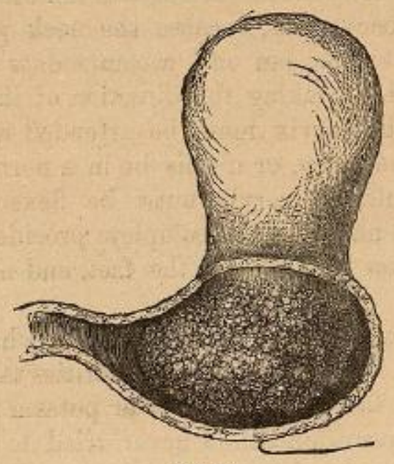

Fig. 74.

A lady from Connecticut was sent to the Woman's Hospital in October, 1860, with a cancroid tumour of the cervix, about the size of a Sicily orange. It grew from the whole cervix. Fig. 74 is intended to represent its relative size and position. There was no doubt as to the nature of the disease, nevertheless it was determined to remove it. The patient was etherized, and placed on the left side, as in all such operations. The speculum was introduced, and the chain of the écraseur was carried around the base of the tumour, just at the reduplication of the vaginal cul-de-sac antero-posteriorly, the parts remaining *in situ* as represented in the diagram.

The écraseur was worked in the usual way; the late Professor V. Mott was sitting on my right, watching the process. He had great objections to the instrument on

philosophic grounds, and I was anxious to prove to him that it should be accepted as a valuable addition to our surgical resources, which, however, I failed to do. He was on the eve of leaving before the operation was finished, when I said, "Please wait a few minutes, Doctor; it is almost through." He sat down again, and in a moment I was surprised by the sound of air rushing in and out of the vagina, with all the regularity of, and synchronously with, inspiration and expiration, at the same time that the tumour, obeying the slight traction on the écraseur, came without the least resistance to the mouth of the vagina. Two or three quick turns of the chain cut it off entirely, and on its removal I was horrified to find an immense hole of a semilunar form, in the cul-de-sac of the vagina, through which we could look for three or four inches up into the peritoneal cavity, and observe the movements of the viscera with every respiratory act.

Fig. 75 represents the appearances of the parts. The

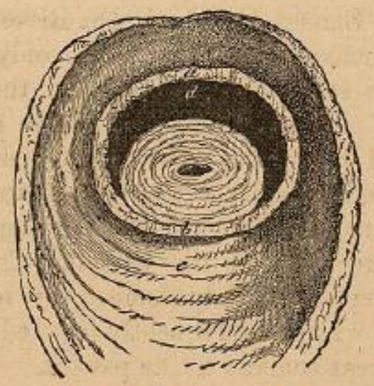

Fig. 75.

uterus adhered anteriorly at *b*, but posteriorly and laterally it was completely severed from all vaginal con-

nections. To have closed the parts properly, we should have united the edge of the posterior cul-de-sac *a* to the posterior portion of the uterus from which it was separated; but as we all looked upon the case as necessarily and immediately fatal, and as the nice adaptation of the parts would have been tedious, compelling us to keep our patient longer under the influence of ether than we wished, we concluded to make quick work of it. The edges of the vagina anteriorly, and all the way around, were rapidly denuded, and six silver sutures were passed, as in the operation for vesico-vaginal fistula, and the two opposite borders of the vagina were neatly approximated, leaving the neck of the uterus within the peritoneal cavity. But for the drainage of its secretions a catheter was passed into the peritoneal cavity at the central point of union opposite *c*, which was left slightly open for this purpose. A severe peritonitis followed, from which she fortunately recovered.

This operation was witnessed by a large concourse of medical gentlemen; amongst whom were the venerable Dr. Mott, Dr. Emmet, Dr. Pratt, Dr. Rives, then house-surgeon, and many others. It is the only instance in which I have seen any accident from the use of the écraseur. Of course the inclosure of the cervix within the peritoneal cavity was all wrong, and should not be done again under similar circumstances, and would not have been done then if we had had the remotest idea of the possible recovery of the patient. The peritoneal cavity was kept constantly drained, by means of the tube, through which we frequently injected tepid water, which gave great comfort to the patient.

It was worn for about three weeks, when the opening became fistulous and remained patent. Greatly to my surprise, the patient recovered entirely from the

effects of the operation, and in a few weeks returned home in a very comfortable condition; but soon symptoms of the old cancroid disease began to manifest themselves, and she died of cancer some eight or ten months after leaving the Hospital. The idea of drainage-tubes for the peritoneal cavity, and of injecting this cavity through them, belongs to my countryman Dr. Peaslee, who has fully established the safety and efficiency of the practice, after the operation of ovariotomy, where there are poisonous secretions to be evacuated. The reader will find Dr. Peaslee's cases reported in the *American Journal of the Medical Sciences.**

Amputation of the cervix uteri belongs essentially to French surgery. It was a very frequent operation in the hands of Lisfranc. He amputated the cervix in ninety-seven cases, and lost but two patients.

Lately Huguier has brought it more prominently before the profession in generalizing it for all cases of what he terms hypertrophic elongation. His success is all that could be desired. Huguier's were all procidentia cases, mostly with elongation of the supra-vaginal portion of the cervix; but we are here to consider the operation as applicable only to infra-vaginal elongation, without necessarily a procidentia.

In my early amputations with the écraseur, the os tincæ was so often puckered and contracted, that I adopted the plan of doing the operation at two periods; thus, I would with scissors split the cervix bilaterally, nearly down to the insertion of the vagina, and then remove one-half of it; for instance, the anterior portion *a*, at *b* (fig. 76); wait one or two menstrual periods

* *American Journal of the Medical Sciences*, January, 1856, p. 49, April, 1863, p. 363; July, 1864, p. 47.

for the parts to heal, and then remove the remaining half.

This was getting to be the method pretty generally adopted at the Woman's Hospital till October, 1859,

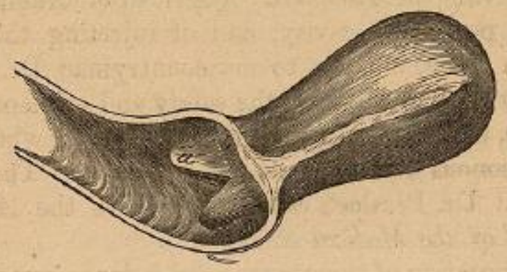

Fig. 76.

when we hit upon the following plan and in the following way. A lady from North Carolina was sent to me by her physician for amputation of the cervix. Her time being limited, she was very anxious to return home as soon as possible. I therefore determined to remove the whole cervix at one operation with the écraseur. Just as she was fully etherized, Dr. Pratt, the house-surgeon, reported that our only écraseur was broken; and without any choice in the matter, I was compelled to amputate with scissors. By hooking a tenaculum in the anterior lip of the os tincæ, the cervix was pulled gently forwards, and held firmly, while with scissors it was split bilaterally nearly to the insertion of the vagina, still holding on with the tenaculum; the anterior half was quickly cut off with scissors and then the posterior half. I intended to leave the stump to heal over in the usual way by the granulating process, which would have taken from three to five or six weeks, but, while examining the wound, and waiting for the bleeding to cease, the idea all at once occurred to me to cover over the cut

surface with vaginal mucous membrane, just as we cover over the stump of an amputated arm or leg by skin, after the circular method. I immediately passed four silver sutures, two on each side of the canal of the cervix, through the cut edges of the vagina, antero-posteriorly, which drew this membrane over the stump of the cervix, covering it completely, but leaving a small oval opening in the centre to correspond with that of the cervical canal.

The parts healed by the first intention; the sutures were removed in nine or ten days, and my patient was soon on her way home, not having suffered in the least from the effects of the operation. From that time on I have adopted this method of amputation, and have every reason to think that the healing by the first intention in this operation is relatively as superior to that by granulation as it is in any other amputation.

Fig. 77 represents the cervix after amputation, with

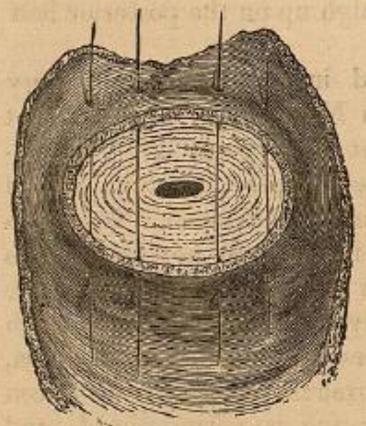

Fig. 77.

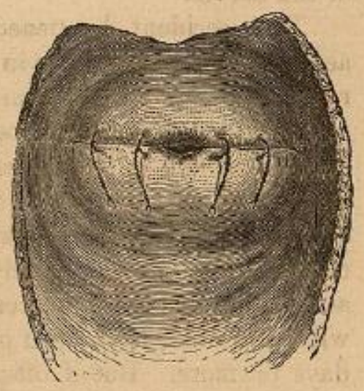

Fig. 78.

the wires passed through the cut edges of the vagina ready for covering over the stump.

Fig. 78 is to represent the appearance of the stump after the sutures are twisted and cut off.

But it may be asked what are the risks of the operation? I think they are few. Lisfranc lost two patients out of ninety-seven; Huguier operated thirteen times without any bad result. I have operated more than fifty times, thirty-six by this method, and lost one patient. This case occurred unfortunately just at a time when the hospital atmosphere suddenly became unfavourable to all surgical operations, and we had serious accidents to follow the slightest operation, before we were aware that we were breathing a poisoned air. If we had known of this epidemic condition, this patient would not have been operated upon at that time, for such was the state of our over-crowded wards that we were obliged to thin them out, and stop all operations for five or six weeks. But is there no danger in the operation *per se?* The only one that I know of is that of opening the peritoneal cavity by cutting too high up on the posterior half of the cervix.

This accident happened in the hands of a very accomplished accoucheur in New York, and his patient recovered without the least bad symptom. But, notwithstanding this fortunate escape, it must be looked upon as a danger to be carefully avoided. Take this method of amputation all in all, I do not think it is attended with any more risk than that of incision of the os and cervix. Theoretically it should be safer, inasmuch as the one is healed universally by the first intention, while the other is an open granulating surface for fifteen days or more. But if offspring be very desirable, and if a long cervix should seem to be the only or principal barrier, there are but few women who would not take

the slight risks of the operation for the fulfilment of a hope so precious.

I have not as yet had many cases of pregnancy to follow amputation of the cervix, but I am well satisfied now, that if amputation had been performed in many cases in which I simply cut the open cervix, conception might have occurred, where it has not.

On page 194 is recorded a case of pregnancy following the amputation, or rather exsection of the posterior portion of the cervix; and I have another case where it followed the removal of the anterior half of the cervix. The circumstances were these. Mrs. A., aged thirty; married seven years; one child six years ago; it died young; no conception since; very anxious for offspring; exceedingly unhappy. A minute detail of symptoms is unnecessary. She had retroversion, with hypertrophy of the posterior wall of the uterus; while the cervix was hypertrophied, elongated, and indurated. She was under treatment at times from October, 1857, to the spring of 1859. From the very beginning I told her I did not see how she could ever conceive with such a condition of the neck of the womb; and I wished then to amputate it, but she was afraid of the operation, and could not make up her mind to it. At last I told her that I could not expend any more time on her case, unless she submitted to amputation of the cervix. She consented, and entered the Woman's Hospital. I was then in the habit of performing the operation at two periods.

Dr. Francis, Dr. Mott, and Dr. Green, of the consulting board, and Dr. Emmet, were present at the operation on the 8th July, 1859. The cervix was split bilaterally with scissors, and the anterior half was removed. She left the hospital in a fortnight, with the expectation of

returning on the 1st of October for the removal of the other half. But fortunately the next menstruation was followed by conception. She went the full term, and was safely delivered.

In 1862 the greatest number of my amputations were performed. It was then a question with many of my medical friends whether the operation would not in itself prove a barrier to conception. The case of half-amputation above related, and the one on page 194, were then my only facts bearing on the question. But now I have two cases proving that it in no way interferes with conception. It is true that in these the operation was not performed with any view to conception, but simply for the removal of disease that baffled all other treatment. One was a patient of Professor Metcalfe, of New York. She was the mother of one child, and had been in bad health ever since its birth.

The position of the uterus was normal, the cervix was hypertrophied, but not indurated, the os was lacerated back through the posterior lip, nearly to the insertion of the vagina, and the cervical mucous membrane projected in voluminous granular folds, giving rise to constant leucorrhœa. Various remedies had been used without any improvement; and as Doctor Metcalfe had already exhausted our routine of local treatment, I proposed amputation as the speediest and surest method of getting rid of the diseased condition, and the operation was done in May, 1862, Dr. Metcalfe, Dr. T. G. Thomas, and Dr. Emmet assisting. The operation was performed as already described, and the stump covered over with vaginal mucous membrane by passing the sutures antero-posteriorly. Hæmorrhage came on two or three days afterwards, which gave Dr. Metcalfe and Dr. Thomas a little trouble; but she soon got well without any other

accident; and Dr. Emmet writes me that conception occurred four months after the operation.

The other case was that of a lady who had borne one child four years before. She is the daughter of an eminent physician. She had retroversion with enlargement of the posterior wall, and hypertrophic elongation of the cervix. This condition of the cervix seemed to be a barrier to a rectification of the malposition, and it was determined to amputate it. With the assistance of Dr. Emmet and Dr. Pratt, the operation was performed in June, 1862, and she conceived in October following.

These facts I present as an answer to any question in regard to the influence of amputation upon conception, and to show that the operation *per se* does not interfere with it. I have been minute and a little tedious in detail, because I shall soon have occasion to insist on the performance of this operation in a class of cases where, as yet, it has not been recommended.

An opposite condition of the cervix, viz., defective development, may be a cause of sterility, and I may mention it in this relation. We occasionally find the womb undeveloped or in quite a rudimentary state, and here menstruation may be wholly absent, or so slight as scarcely to attract attention. In such cases little or nothing is to be done. But now and then we find the womb large enough, and menstruation abundant, but the cervix does not project into the vagina. These are always sterile and usually dysmenorrhœal. The canal of the cervix will be very small and usually flexed.

As a type, I may give an illustration. Dr. W. E. Johnston called on me in December, 1863, with a patient of his, who had been married ten years without issue. She had consulted Velpeau, Nélaton, Ricord,

Trousseau, and thirty-two other physicians of Paris. Her dysmenorrhœa was fearful. She usually took anodynes, and had leeches applied by the speculum at each menstrual period. The symptoms and sufferings of such cases are too well known to require detail here. The finger passed into the vagina, found only a blind pouch, but it was sufficiently capacious. No cervix projected into it, but the uterus could be felt on the right of the mesial line, sitting, as it were, on the vagina, and attached to it by a narrow crooked isthmus of fibrous tissue, which was the undeveloped cervix, along which a probe could be passed to the fundus, a depth of two inches and a half. On the left of the uterus was a mass of condensed cellular tissue half the size of an English walnut, probably the remains of a pelvic abscess that occurred some four or five years ago. The circle *a b* (fig. 79) represents the place that should have been occupied by the cervix, while the point *c* shows the actual opening leading to the uterus.

FIG. 79.

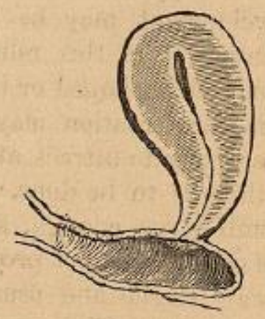

FIG. 80.

This point was once more obscure than at present, and some one of her physicians had split up a bit of vaginal membrane that overlapped, and made the canal more

valvular and tortuous than it is now; still this produced no improvement in her sufferings.

Fig. 80 shows the neck of the womb resting on the vagina instead of projecting into it. Of course there would be but one course here to pursue, viz., to cut open the canal of the cervix, and keep it open afterwards. But the operation would require great nicety, on account of the narrow undeveloped state of the cervix just where it comes in contact with the vagina. However, nothing was attempted in this case; she was an only child, and her father was afraid to let her submit to a surgical operation.

But let us leave these extreme cases, whether of hypertrophic or defective development, and pass to the consideration of such conditions of the cervix as we meet commonly and daily in sterile women.

At the beginning of this section I said, "the cervix should be of proper size, form, and density." Having now spoken of the size and its variations, we may ask ourselves what is a proper form or shape.

It should be rounded and truncated. Now, if we turn back to the table on page 199, we will see that of 218 sterile women the cervix was flexed in 71. Of these, 19 were supra-vaginal curvatures complicated with some version of the fundus from a normal position. The flexure was associated with a conoid form in 52 cases, in some of which there were also malpositions of the body. It was straight, conical, and indurated in 4; straight, conical, indurated, and elongated in 109; straight, conical, elongated, and not indurated in 7; granular and conical in 3.

It is thus shown that a conoid form of the cervix, whether flexed, straight, elongated, or not, is found in the great majority of cases naturally sterile, being here

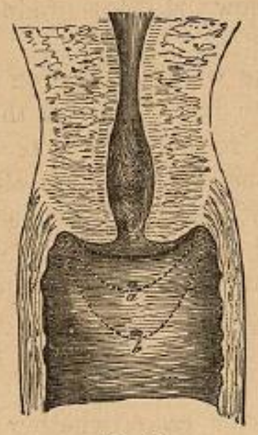

Fig. 81.

175 out of 218. We must discriminate between natural and acquired, or accidental sterility; and here let it be remembered that we speak only of those married women who have never conceived.

I know not how I can better describe what I mean by a conical cervix than by diagrams. Let fig. 81 represent a normal type of a rounded, truncated cervix. Now, if we imagine the cervix extended in the direction of the dotted line *a*, we shall have a not unfrequent form of conoid cervix, which will almost universally be associated with a contracted os, and be almost as constantly indurated. A moderate degree of conoidity like this may be remedied very easily, and if everything else is right, we may calculate with a good deal of certainty on the removal of the sterility. For this purpose the operation of incising the os and cervix as for dysmenorrhœa will suffice. The operation does not alone enlarge the os, but if the circular fibres of the cervix be properly and thoroughly divided, the lips of the os tincæ, instead of being puckered to a little round point, evert and roll back from each other, giving the cervix more of the natural feel of a truncated cone than of a pointed one, as before; and thus while it becomes truncated it also becomes shorter, or, in other words, while it assumes a more natural form, it also takes on a more natural size. This is the mildest and most favourable of the conoid form. Its type is represented in fig. 65, p. 180. But

if the cervix be extended in the direction of the dotted line *b*, then its mere incision will not so easily restore it to anything like a normal condition.

We sometimes find the cervix as conical as a mole's head, gradually tapering from the insertion of the vagina almost to a point at the os tincæ, being very much longer than it is broad. Calling to mind the fact that in 218 cases it was straight, conical, and elongated in 116, or more than half, I now think that the great mistake I have made in the treatment of these cases, was that of simply incising the os and cervix; and the same mistake has been made by all other surgeons.

I now propose to amputate a portion of the cervix in all such cases, for the purpose of giving it as near a normal form as possible. For instance, in fig. 82, let the cervix be amputated at the point designated by the dotted line.

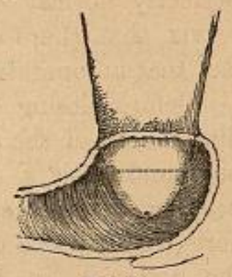

Fig. 82.

We have all been afraid to truncate the cervix in this way (if any of us ever thought of it before), and were satisfied with simply splitting it up for the relief of the pain of menstruation, thinking that if we were successful in this we might hope for success in other things. I have cut open the neck of the womb, and often seen conception follow soon after; and I have cut open scores, nay, hundreds of others, sometimes with relief to suffering; but how often have I been disappointed in the great object of the operation! And why? I now see that, in many cases, more must be done than to open the canal of the cervix.

When I run my eye over the list of cases in which

the operation has been quickly followed by conception, I discover that while almost all had a contracted os, all had also a cervix of no unusual length; and when I examine closely all those who have had a division of the os and cervix without its being followed by conception, I find almost every one of them either with an elongated conical cervix, or with some other complication equally if not more unfavourable. Does not the inference follow from this, that if we expect to treat such cases with more certainty and greater success, we must, other things being equal, approximate a normal condition as much as possible, by truncating the cervix to a proper size and form?

It was but the other day I had the opportunity of examining the cervix of an unmarried lady upon whom I had performed amputation two years ago; and so perfectly normal was the appearance of the os and cervix, that there were no evidences whatever of the fact that an operation had ever been done.

Before closing this subject, I may give a few more illustrations of the conical cervix. For instance, it may be found with a flexure, the anterior and posterior portions being unequally developed, as in fig. 83; and here we may cut open the cervix bilaterally, or split the posterior lip directly backwards; but I think it would be much better to amputate in the direction of the dotted line, and afterwards to cut open the cervix bilaterally, if the prime object of all treatment be offspring.

Again, we may have the conical cervix with a straight canal; the whole organ having the feel of a hard inverted cone (fig. 84).

These cases I have always cut open bilaterally, but I can call to mind few that were followed by conception.

In all such cases I am now very sure that it would be better to amputate, and restore the cervix at once to a normal condition.

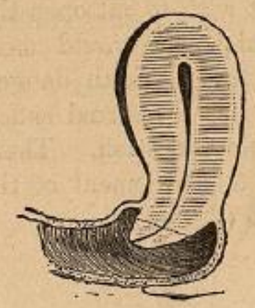

Fig. 83.

Fig. 84.

It is not at all uncommon to find a concoid cervix accompanied with retroversion. Sometimes the malposition seems to be the result of the elongated conoid cervix pressing against the posterior wall of the vagina. Conception is impossible in a womb of this relative size, form, and position (fig. 85).

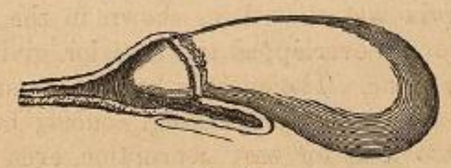

Fig. 85.

These examples of conoidity are enough to impress upon our minds its general character and appearance; but there are cases that cannot be called conoid, and yet are to be treated in the same way if we expect offspring. For example, I saw, in consultation in Paris, in May, 1863, a lady, about 27 years old, who had been

married six or seven years without offspring. She had had dysmenorrhœa ever since her marriage, and had been treated by very distinguished physicians, one of whom told her that she might possibly fall into the hands of some surgeon who might wish to cut open the neck of the womb, against which he would most seriously protest, as an operation fraught with danger. It is useless for me to dwell upon her menstrual sufferings, and general nervous, irritable condition. There was anteversion, with hypertrophic enlargement of the fundus antero-posteriorly, as at *a*, *b* (fig. 86).

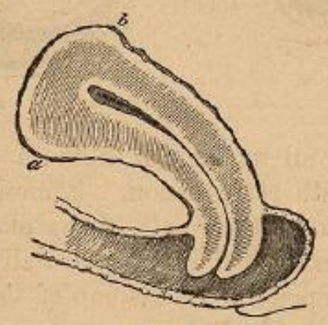

FIG. 86.

The cervix was curved, as shown in the diagram. The posterior lip overlapped the anterior, giving the os a crescentic shape. The anterior lip was granular. The cervix was not, properly speaking, conoid; but it was elongated, too long for easy conception, even if it had been straight and patulous. The canal of the cervix could not be called contracted, and yet the flexure was such as to bring the antero-posterior surfaces in close apposition, like laying the bowl of one spoon in another, which always presents a very complete obstruction to the egress of the menstrual flow. As a consequence of this mechanical barrier, she had a persistent endometritis, as

seen by the dark brownish mucus that was always found hanging from the cervical canal.

I here proposed to divide the cervix bilaterally, at the same time saying that amputation would give us a better chance for permanent relief.

Her medical attendant agreed to the operation of incising the os and cervix. Our object was to relieve the dysmenorrhœa and endometritis by opening the canal, knowing full well that it would be a most difficult thing to render it permanent unless we could keep the posterior lip everted or rolled backwards. However, the operation was thus performed, much against the wishes of the patient herself, who begged for amputation, as affording her the surest, if not the safest, method of cure. Her first menstruation after the operation was entirely painless, but unfortunately it did not remain so, and further treatment was necessary. In cases like this I am sure it would be better to amputate the cervix first, and then incise it at some subsequent period.

If experience should prove that I am correct in my views in regard to the necessity of amputating an elongated conoid cervix, for the purpose of augmenting the chances of conception, I feel that it is important to simplify the operation as much as possible. The amputation of the cervix by scissors, as I have always done it, is easy enough in the hands of a practised surgeon, but every one will not find it always so easy to make a good even stump by this method. I have not been able to get a pair of scissors curved sufficiently to do the work neatly. But I think I have at last hit upon something better, which I would term the uterine guillotine. This instrument is made in London by Mayer, and in Paris by Charrière. The idea of the uterine guillotine occurred to me in this way. In July last (1865) my

friend Dr. Henry Bennet invited me to amputate an elongated hypertrophied cervix in a patient of his who had had procidentia for a long time. The cervix projected from the vulva about an inch and a half. It was necessary to remove three-fourths of an inch of it. Dr.



Fig. 87.

Bennet held the uterus firmly with a double tenaculum forceps (fig. 87), seizing the cervix antero-posteriorly, just above the point of election for the amputation. I then caught hold of the end of the cervix, and with a bistourie cut it instantly off. The stump was covered over with mucous membrane in the usual way with silver sutures. The operation was done so quickly and withal so neatly, that I immediately said, "Why should we not have an instrument, like those for the tonsils, to amputate the cervix all at once, while the organ is *in situ?*" This idea I gave to Mr. Mayer, and fig. 88 represents the instrument. It consists simply in adding a blade to the écraseur. At first I had a wire to constrict the part to be amputated, but I found that it would bend a little from a right line when tightened, and so strike the edge of the knife as it was pushed forwards; then, at M. Charrière's suggestion, a loop of narrow watch spring doubled three or four times was substituted, giving a flat surface along which the blade glides without obstruction.

In applying the instrument, let the loop *f* encircle the cervix where we wish to cut it off; turn the screw-nut *b* till the loop embraces the part firmly and immovably; transfix the cervix with the needle by means of the slide *d;* then push the blade *e* quickly forwards by forcing down the shaft *a*, and the part will be instantly cut through. The dotted lines *l*, *i*, *j* show the relations of the loop, needle, and knife, when the operation is finished. The patient is to be, of course, in the left lateral semi-prone position, and the operation executed without traction on the uterus. The stump is to be covered over with mucous membrane, as previously described and figured (p. 207). There is always some contraction of the os externum after all amputations of the cervix. It is better as a rule to let things take their course, and in two or three months afterwards cut open the os and cervix, and treat it just as we would under ordinary circumstances requiring such an operation. If we attempt to keep the os normally open, there is danger of interfering with the covering of the stump; and if we resort to the operation of incising it too soon after the amputation, say just after the next menstrual flow, we may in our manipulations tear the vaginal covering of the stump from the surface to which it has

Fig. 88.

recently adhered. I have had this accident happen in my own hands; and hence the warning to guard against it.

Induration of the cervix is so often an attendant of the sterile condition that it is appropriate to speak of it here in connection with the size and form of the cervix. It may be natural or acquired; natural when we find a little gristly-feeling cervix in a dysmenorrhœal case, where there is often a small fibroid in the anterior wall of the uterus; acquired, when we find it following a chronic inflammation of the cervix, in which the granular condition disappears after a very long time and perhaps a long treatment. I have no specific treatment to suggest, and I look upon it as important, more particularly as it may influence the size, form, and relations of the os and cervix. If there is a deposit of fibrous tissue in the cervix, as a result of inflammatory action, I know of no short way of causing its absorption, and I deal with it only incidentally, as my attention is directed to the rectification of the anatomical and mechanical peculiarities already discussed. I know that physicians give alteratives, absorbents, and general constitutional remedies, and apply all sorts of things locally; that they melt down the cervix with potassa cum calce; but even then the induration remains; and I would prefer immediate amputation to this tedious uncertain process. It is supposed that the drain of the caustic issue softens the parts; but I have not seen it so, and some years ago I often used this potent agent. I must say, however, that Professor Fleetwood Churchill's iodine treatment has in my hands produced a greater amelioration in these cases than anything else; but it is tedious. Dr. Churchill tells me that I have failed with it because I have not persevered long enough in its use. I beg leave here to

refer the reader to his learned and classic work on the Diseases of Women for minute information on this point.

Dr. Barnes has recently (June 7th, 1865) presented a paper to the London Obstetrical Society, in which he discusses very ably the influence exercised by the conoid cervix upon the sterile condition. The following summary* is extracted from the report of the Secretary, Dr. Meadows:—"Dr. Barnes described and figured the form of cervix uteri which projected into the vagina as a conical body, the vagina appearing to be reflected off at a point nearer the os internum than normal. The os externum was unusually minute, scarcely admitting the uterine sound. This (the os externum) was the real seat of constriction. The os internum was normally a narrow opening, and in these cases of dysmenorrhœa and sterility it was commonly found to be of normal character. It was therefore unnecessary to divide it. It was, moreover, dangerous to divide it, on account of the close proximity of the large vessels and plexuses running into the uterus on a level with it. . . . . Discussing the question of treatment, Dr. Barnes showed that dilatation was unsatisfactory; that incision of the os internum as practised by Dr. Simpson's single bistourie caché, and by Dr. Greenhalgh's double bistourie caché, was unsafe and superfluous. He objected to the latter instrument, especially that it must cut as it was set, that it was too much of an automatic machine, not leaving scope for the judgment of the operator. His (Dr. Barnes's) own instrument, constructed like a pair of

* *Lancet*, July 15th, 1865: "On the Dysmenorrhœa, Metrorrhagia, Ovaritis, and Sterility associated with a Peculiar Form of the Cervix Uteri, and the Treatment by Division." By Robert Barnes, M.D.

scissors, acted on the same principle as Dr. Sims's; it divided only the os externum, so as to open the cavity of the cervix, the part to be cut being first seized between the two blades. The operation was perfectly free from risk; the hæmorrhage was usually slight, and a good os was made. He had performed the operation many times, both in hospital and private practice, and was well satisfied with the results. One advantage of incision over dilatation was, that it relieved the engorgement and inflammation."

Dr. Barnes's admirable paper gave rise to a lengthened discussion; he and Mr. Baker Brown alone, amongst all the speakers, holding the same views that I do in regard to the relative infrequency of contraction at the os internum as compared with that at the os externum.

SECTION V.

THE UTERUS SHOULD BE IN A NORMAL POSITION—*i. e.*, NEITHER ANTEVERTED NOR RETROVERTED TO ANY GREAT DEGREE.