the development of swelling of the left leg. In the cases reported by Andrew, Church, Tuckwell, Isambard Owen, and Wilks the patients had headache, vomiting, and delirium. Paralysis was not present. In Douglas Powell's case, with similar symptoms, there was loss of power on the left side. Bristowe reports a case of great interest in an anæmic girl of nineteen, who had convulsions, drowsiness, and vomiting. Tenderness and swelling developed in the position of the right internal jugular vein, and a few days later on the opposite side. The diagnosis was rendered definite by the occurrence of phlebitis in the veins of the right leg. The patient recovered.

The onset of such symptoms as have been mentioned in an anæmic or chlorotic girl should lead to the suspicion of cerebral thrombosis. In infants the diagnosis can rarely be made. Involvement of the cavernous sinus may cause œdema about the eyelids or prominence of the eyes.

In the *secondary thrombi* the symptoms are commonly those of septicæmia. For instance, in over seventy per cent of Pitt's cases the mode of death was by pulmonary pyæmia. This author draws the following important conclusions: (1) The disease spreads oftener from the posterior wall of the middle ear than from the mastoid cells. (2) The otorrhœa is generally of some standing, but not always. (3) The onset is sudden, the chief symptoms being pyrexia, rigors, pains in the occipital region and in the neck, associated with a septicæmic condition. (4) Well-marked optic neuritis may be present. (5) The appearance of acute local pulmonary mischief or of distant suppuration is almost conclusive of thrombosis. (6) The average duration is about three weeks, and death is generally from pulmonary pyæmia. The chief points in the diagnosis may be gathered from these statements.

Pitt records an interesting case of recovery in a boy of ten, who had otorrhœa for years and was admitted with fever, earache, tenderness, and œdema. A week later he had a rigor, and optic neuritis developed on the right side. The mastoid was explored unsuccessfully. The fever and chills persisting, two days later the lateral sinus was explored. A mass of foul clot was removed and the jugular vein was tied, after which the boy made a satisfactory recovery.

III. AFFECTIONS OF THE SUBSTANCE.

I. Topical Diagnosis.

A majority of the lesions of the nervous system which permit of a local diagnosis have as an important part of their symptomatology disturbance of muscular action, and as our knowledge of the mechanism governing the movements of muscles is comparatively exact, we shall take this system as a basis for local diagnosis.

The motor system is made up of two segments, each consisting of groups of nerve-cells, and their prolongations into nerve-fibres. The *upper segment* comprises the motor cortex and the pryamidal fibres; and the *lower segment* the motor cells in the medulla and cord and the nerve-fibres arising from them, forming the peripheral nerves distributed to the muscles, which may themselves be considered as part of this segment.

The nerve-cells are so arranged that when thrown into action, by whatever cause, a definite movement is the result, and the same combination of nerve-cells always causes the same movement, or, in other words, every movement of the body is represented in the nervous centres by combinations of the nerve-cells, or, as we say, is localized.

Movements are localized both in the cells of the lower segment and in those of the upper, and we have consequently spinal localization and cerebral localization.

Spinal Localization.—In the lower motor segment the muscles are represented in their simplest movements, and different sections of the cord have been found to represent the movements of different muscles. Our knowledge of this localization is by no means complete, but enough has been learned to aid us materially in determining the site of a spinal lesion.

The cells of the lower segment are found in the motor nuclei of the medulla, and in the anterior gray horns of the spinal cord. They are connected with the muscles by the axis cylinder processes, the anterior nerve-roots (roots of motor cranial nerves), the peripheral nerves, and the end organs by which they are brought into intimate relation with the protoplasm of the muscle fibre itself.

The following table prepared by Starr gives in detail our knowledge on this subject:

Localization of the Functions of the Segments of the Spinal Cord.

Segment.	Muscles.	Reflex.	Sensation.
II and III C.	Sterno-mastoid. Trapezius. Scaleni and neck. Diaphragm.	Hypchondrium (?). Sudden inspiration produced by sudden pressure beneath the lower border of ribs.	Back of head to vertex. Neck.

Segment.	Muscles.	Reflex.	Sensation.
IV C.	Diaphragm. Deltoid. Biceps. Coraco-brachialis. Supinator longus. Rhomboid. Supra and infra spinatus.	Pupil. 4th to 7th cervical. Dilatation of the pupil produced by irritation of neck.	Neck. Upper shoulder. Outer arm.
V C.	Deltoid. Biceps. Coraco-brachialis. Brachialis anticus. Supinator longus. Supinator brevis. Rhomboid. Teres minor. Pectoralis (clavicular part). Serratus magnus.	Scapular. 5th cervical to 1st dorsal. Irritation of skin over the scapula produces contraction of the scapular muscles. Supinator longus. Tapping its tendon in wrist produces flexion of forearm.	Back of shoulder and arm. Outer side of arm and forearm, front and back.
VI C.	Biceps. Brachialis anticus. Pectoralis (clavicular part). Serratus magnus. Triceps. Extensors of wrist and fingers. Pronators.	Triceps. 5th to 6th cervical. Tapping elbow tendon produces extension of forearm. Posterior wrist. 6th to 8th cervical. Tapping tendons causes extension of hand.	Outer side of forearm, front and back. Outer half of hand.
VII C.	Triceps (long head). Extensors of wrist and fingers. Pronators of wrist. Flexors of wrist. Subscapular. Pectoralis (costal part). Latisimus dorsi. Teres major.	Anterior wrist. 7th to 8th cervical. Tapping anterior tendons causes flexion of wrist. Palmar. 7th cervical to 1st dorsal. Stroking palm causes closure of fingers.	Inner side and back of arm and forearm. Radial half of the hand.
VIII C.	Flexors of wrist and fingers. Intrinsic muscles of hand.		Forearm and hand, inner half.
I D.	Extensors of thumb. Intrinsic hand muscles. Thenar and hypothenar eminences.		Forearm, inner half. Ulnar distribution to hand.
II to XII D.	Muscles of back and abdomen. Erectores spinæ.	Epigastric. 4th to 7th dorsal. Tickling mammary regions causes retraction of epigastrium. Abdominal. 7th to 11th dorsal. Stroking side of abdomen causes retraction of belly.	Skin of chest and abdomen in bands running around and downward, corresponding to spinal nerves. Upper gluteal region.
I L.	Ilio-psoas. Sartorius. Muscles of abdomen.	Cremasteric. 1st to 3d lumbar. Stroking inner thigh causes retraction of scrotum.	Skin over groin and front of scrotum.

Segment.	Muscles.	Reflex.	Sensation.
II L.	Ilio-psoas. Sartorius. Flexors of knee (Remak). Quadriceps femoris.	Patella tendon. Stroking tendon causes extension of leg.	Outer side of thigh.
III L.	Quadriceps femoris. Inner rotators of thigh. Abductors of thigh.		Front and inner side of thigh.
IV L.	Abductors of thigh. Adductors of thigh. Flexors of knee (Ferrier). Tibialis anticus.	Gluteal. 4th to 5th lumbar. Stroking buttock causes dimpling in fold of buttock.	Inner side of thigh and leg to ankle. Inner side of foot.
V L.	Outward rotators of thigh. Flexors of knee (Ferrier). Flexors of ankle. Extensors of toes.		Back of thigh, back of leg, and outer part of foot.
I to II S.	Flexors of ankle. Long flexor of toes. Peronæi. Intrinsic muscles of foot.	Plantar. Tickling sole of foot causes flexion of toes and retraction of leg.	Back of thigh. Leg and foot, outer side.
III to V S.	Perineal muscles.	Foot reflex. Achilles tendon. Overextension of foot causes rapid flexion; ankle-clonus. Bladder and rectal centres.	Skin over sacrum. Anus. Perinæum. Genitals.

Cerebral Motor Localization.—In the motor cortex the muscles are again represented, or, as Hughlings Jackson says, re-represented in their finer movements.

Motor Centres.—The experiments of Hitzig and Fritsch and of Ferrier, together with the previous clinical studies of Hughlings Jackson, laid the foundation of our present knowledge of cerebral localization.

The area for representation of the movements in the cerebral cortex is in the Rolandic region and comprises the ascending parietal and ascending frontal convolutions, the hinder part of the three frontal convolutions, and the parietal lobule, a continuation backward of the ascending parietal convolution (Fig. 2, motor region). This entire region is excitable, and stimulation by weak electrical currents produces muscular movements in the opposite half of the body. The centres presiding over the different groups of muscles may be thus classified:

(*a*) Centres for the trunk. These have been shown by Schäfer to be situated in the marginal gyrus, just within the longitudinal fissure, the region sometimes spoken of as the paracental lobule.

(*b*) Centres for the lower limbs. These are situated at the upper part of the Rolandic region, close to the longitudinal fissure. As indicated in the diagram, the representation of movements of the different portions of the lower limb in this region is as follows (Fig. 2): Most anterior, the hip; next in order, the knee and ankle; then the big toe, the centre for

the movement of which surrounds the upper end of the fissure of Rolando. Still further back are the centres for movement of the small toes.

(*c*) Centres for the upper limbs. This area corresponds to about the

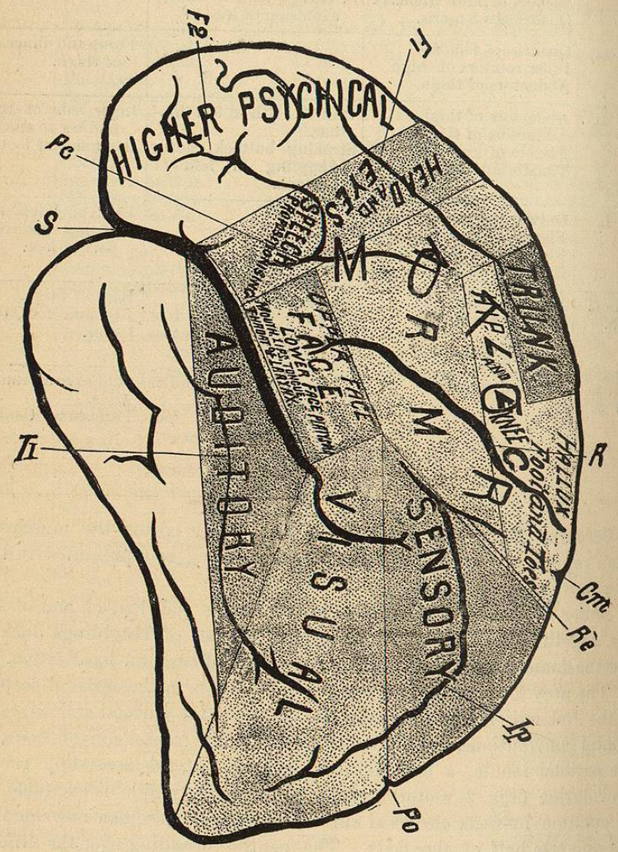

FIG. 2.—(After Mills). This diagram approximately indicates the views now held as a result of experiment and their confirmation or modification by clinico-pathological observation. It represents the division of the lateral surface of the cerebrum into higher psychical, motor, sensory, visual, and auditory areas; also the subdivision of the motor area into subareas for speech, the head and eyes, the face, arm, leg, and trunk. Only certain main points have been indicated by lettering, so as not to confuse: *S*, fissure of Sylvius; *R*, fissure of Rolando, or central fissure; *Pc*, precentral fissure; *Rc*, retrocentral fissure; *F1*, *F2*, superior and inferior frontal fissure; *Ip*, interparietal fissure; *Po*, parieto-occipital fissure; *T1*, first temporal fissure.

middle two fourths of the motor area. The careful studies of Horsley and Beevor have shown that from above downward the different segments of the limbs are represented as follows: Shoulder, elbow, wrist, fingers, the index-finger, and, lowest of all, the thumb.

(*d*) The centres for the face, tongue, pharynx, and larynx are situated in the lowest portion of the Rolandic area. The centres for the movement of the tongue and vocal cords are in the lower and anterior portion of the ascending convolution, and on the left side in man this region and the posterior part of the third left frontal convolution constitute the speech centre (Fig. 2), destruction of which is followed by one form of aphasia. In front of the precentral sulcus are centres for the representation of movements for turning the head and eyes to the opposite side.

The determination of these areas was worked out in animals and has now been thoroughly established in man, both by clinical observation and by the application of the electrodes in different situations during operations for the removal of growths in the brain or of the motor centres in epilepsy. The different regions must not be regarded as sharply separated from, but as blending with each other.

With these centres for voluntary movements are associated those which preside over the muscular sense, which is a compound of sensory impressions, of pressure, tension, and touch derived from the muscles as they are in motion. There is still dispute with reference to the localization of this sense, but the general opinion is that lesions of the motor area itself cause slight loss both of muscular and tactile sense. Others place the centres for general sensation in the situation marked in Fig. 2.

The fibres uniting the cortical motor centres and the spinal centres have a long course, in which they probably have no connection with any other nerve-cells. They arise from the various centres, enter the white matter of the hemisphere (the corona radiata), and gradually converge to what is called the internal capsule, which lies between the lenticular nucleus and the thalamus and the caudate nucleus (Fig. 3). The position of the fibres in the internal capsule has been accurately worked out by several observers. The fibres from the centres of the face, tongue, eyes, and head occupy the most anterior position, just at the knee, as it is called, of the internal capsule, while the fibres from the upper extremities are just behind these, and those from the lower extremities occupy the position in the middle third of the posterior part. Leaving the internal capsule, the fibres forming the motor path pass from the brain into the crus, in which they occupy a lower and medial position. Passing through the pons, covered by the superficial layers of transverse fibres, they enter the medulla, of which they form the anterior or pyramidal tract. At the lower part of the medulla a large proportion of the fibres decussate and pass into the opposite side of the spinal cord, forming the crossed pyramidal tract of the lateral column, while a smaller number of the fibres descend in the anterior column of the same side, forming the direct pyramidal tract, or

Türck's column. The pyramidal tracts diminish in size from above downward. The fibres enter the gray matter between the anterior and

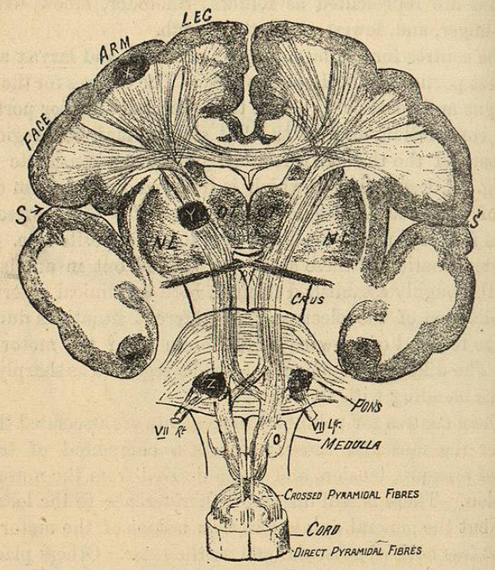

FIG. 3.—MOTOR TRACT (after Starr). *S*, fissure of Sylvius; *NL*, lenticular nucleus; *OT*, optic thalamus; *O*, olivary body. The tracts for the face, arm, and leg gather in the capsule and pass together to the lower pons, where the face-fibres cross to the opposite *VII* nerve nucleus, while the others pass on to the lower medulla, where they partially decussate to enter the lateral columns of the cord; the non-decussating fibres pass to the anterior median columns. The effect of a lesion situated at three points in the tract is shown on the left side of the figure at *X*, *Y*, *Z*. At *Z* the lesion would involve the left facial nerve and the left pyramidal tract above the decussation, producing facial paralysis on the left side and paralysis of the arm and leg on the opposite side—crossed paralysis.

posterior cornua, pass forward, divide and subdivide, and finally join the plexus of the protoplasmic processes, and are in this way connected with the large nerve-cells of the anterior horns.

Lesions of the Motor System.—Each of the segments of the motor tract is to be considered as a nutritional unit, depending for its vitality upon the integrity of its ganglion cells. If certain cells in the cortex are destroyed, the fibres arising from them will degenerate throughout their length—that is, to the beginning of the lower motor segment. So also if the motor cells in the medulla or cord are injured, their nerve-fibres will degenerate, and the muscles to which they are distributed will also be involved in the process. The same thing occurs if the nerve-fibres become detached from their ganglion cells. This process is called secondary

degeneration or Wallerian degeneration, after the physician who first described it. Fig. 4 illustrates this process in the cortico-spinal motor segment.

The lesions may be grouped, as Hughlings Jackson suggested, into negative and positive, or, as they are now more usually termed, destructive and irritative.

Negative or destructive lesions anywhere in the motor path have as a result the abolishment of the functions of these parts—i. e., *paralysis.*

Positive or irritative lesions cause a perversion of the function—i. e., *abnormal muscular contractions.*

Although these two symptoms (paralysis and abnormal contractions) occur whenever the motor path is diseased, each of the segments imparts to them peculiar characteristics which enable us in a great majority of cases to determine the site of a lesion.

These characteristics depend upon, first, the special symptoms referable to the secondary degenerations in the two segments; second, upon their anatomical relation.

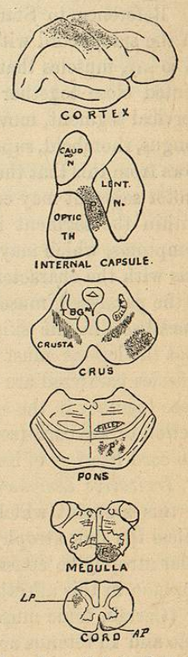

FIG. 4. — (After Gowers.) Diagram showing course and degeneration of pyramidal tract in right hemisphere, crus, pons medulla, and cord.

(*a*) **Lesions of the Lower or Spino-muscular Segment.** *Destructive Lesions.*—The destructive lesions cause here, as everywhere in the motor path, paralysis. We have seen above that when the nerve-fibres are cut off from their ganglion cells in the anterior horns, they not only degenerate themselves, but that the muscles to which they are distributed degenerate. This process is made evident by a change in the electrical reaction of the nerve and muscle—the reaction of degeneration—and the muscle becomes evidently atrophied. The myotatic irritability or muscle reflex, which depends upon the integrity of the lower motor segment, is lost in destructive lesions. This gives to the paralysis certain characteristics, namely, atrophy of the muscles, loss of its reflex excitability, and alteration of the electrical reactions of the nerve and muscle.

The anatomical relations of the lower motor segment also give certain peculiarities, which help to distinguish its lesions from those of the upper segment, on the one hand, and of the different parts of the lower segment on the other.

In general the different units which make up the lower segment are more or less widely separated from each other. An extreme example of