strictly equivalent. The development and comparative anatomy of the organ can hardly be treated upon any other basis; it is recognized in the discussion of encephalic physiology and of psychology, and the descriptive anatomy of the organ is most conveniently based thereon.

§ 40. The segmental constitution of the human brain is invisible from the dorsal aspect (Fig. 664); hardly suggested when the cerebellum as well as the cerebrum is in view; more obvious from the lateral aspect (Fig. 663); still more so from the ventral side (Fig. 672); clearer still from the mesal aspect (Figs. 670, 687, and 756), and unmistakable with early embryos (Figs. 671, 673, and 679), which therefore, but for practical difficulties as to procuring, preserving, and dissecting, would form a natural introduction to human encephalic morphology.

§ 41. *Fig. 672 illustrates:* A. The enormous preponderance of the visible parts of the prosencephal and epencephal over the other segments, thereby occasioning the common and not unnatural though very unphilosophical division of the entire brain into cerebrum (cerebrum proper, olfactory bulbs, and thalami) and cerebellum (with pons and postoblongata), the intervening narrow region, the crura and the quadrigeminum, being regarded as merely an isthmus.* From the morphological standpoint, however, the statement would be nearly reversed. The mesencephal is at one period the most prominent and distinct region (Figs. 671 and 676). The cerebellum may be characterized as an hypertrophied bridge over the "fourth ventricle," and there are some grounds for regarding the olfactory bulbs as primary, and the cerebral hemispheres as their secondary appendages (see my paper, 1887, *a*).

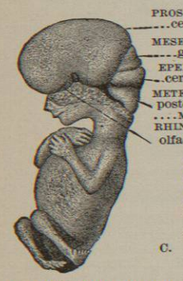

FIG. 673.—Fetus Measuring 49 mm. from Nates to Bregma, and Estimated at Twelve Weeks; 1828. × 1. The specimen was received in alcohol, still enclosed by the membranes. After removal it was pinned to loaded cork and kept under alcohol during the exposure of the brain. The attitude and expression are noteworthy, and have been faithfully reproduced by the photograph and drawing; the right side of the brain is shown in Fig. 746, and the dorsal aspect was published in the *New York Medical Journal*, February 16th, 1884, p. 177.

B. The extension of the cerebrum beyond all other parts of the brain, the occipital lobes overlapping the cerebellum even when the latter is allowed to displace the former. For the relations of these parts in the anthropoid apes, see my paper, 1884, *g*.

C. The lapping of the temporal lobe over the optic tract, as shown by the two interrupted, curved lines on the right (left of the figure).

§ 42. *Fig. 673 illustrates:* A. The general form of the body and limbs at this period.

B. The visibility of all the encephalic segments, excepting the diencephal; even this may be regarded as represented by the optic nerve, dimly seen through the indentation at the ventral margin of the cerebrum.

C. The marked preponderance of the cerebrum.

D. The absence of the transitory fissures; compare, however, the right hemicerebrum, as shown in Fig. 746.

E. The simplicity of the other regions, better shown in Fig. 746; the cerebellum is a narrow and undivided mass; the mesencephal presents a slight transverse depression between the pregeminum and postgeminum.

§ 43. The recognition of the brain as a segmented organ is not dependent upon the determination of the exact number of segments, their equivalency, or their boundaries. The postoblongata represents several *potential* segments or neuromeres, but practically it may be regarded as one. Some even regard the entire oblongata together with the cerebellum and pons as a single segment.

§ 44. Some idea of the diversity of opinion and usage among anatomists with respect to the number and designations of the definitive segments may be gained from the table published in the first edition of this work (viii., 114), which is substantially the same as in my paper, 1885, *b*, and in Wilder and Gage, 1882, 405. The appended Table I. indicates the difference between the verbal schemas adopted by the Anatomische Gesellschaft in 1895, and by the Association of American Anatomists in 1897; the second is followed in the present article.

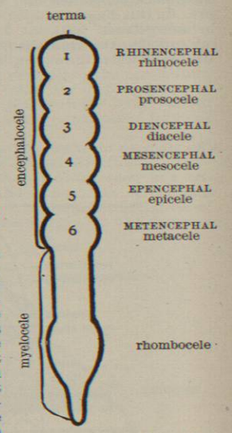

FIG. 674.—Schema of the Neuron (Cerebro-Spinal Axis), as if the cavity were exposed by the removal of the roof. The six encephalic segments are given a conventional spherical form, but without intending to imply that this is their actual shape or that all are separated by constrictions. The main object of the diagram is to associate the encephalic segments with their names and the names of their cavities.

§ 45. *Commentaries on the Schematic Medisected Brain, Fig. 675.*—A. No two original workers in comparative neurology would be likely to construct schemas identical in all respects; the one here presented is not satisfactory to me and I can hardly expect it to suit others. But with all its defects I believe it may serve three useful ends—viz.: (*a*) indicate the relative position of certain parts in the floor or the roof of the general cavity; (*b*) facilitate the recognition of the essential identity of the brains of all vertebrates with that of man; (*c*) stimulate efforts toward the construction of a more perfect schema.

B. Only mesal parts are presented, *i.e.*, such as are divided in a medisection.* This excludes the cerebral hemispheres and olfactory bulbs, the lateral lobes of the cerebellum, and the elevations of the crura and quadrigeminum at the side of the ventral and dorsal mesal furrows.

C. The parietes present four degrees of thickness, viz.: (*a*) thin, *e.g.*, the terma and the tuber in the floor, and in the roof the valvula and the lingula between the thickened quadrigeminum and cerebellum; (*b*) thick, *e.g.*, the two just mentioned, the crura, and the oblongata caudad of the pons; (*c*) reinforced, *e.g.*, the pons, chiasma, and precommissure; (*d*) membranous, consisting only of the endyma and the pia, constituting a tela, *e.g.*, the roofs of the metacele (metatela), of the diacele (diatela), and of the prosocele. The plexuses (metaplexus, etc.) are special modifications of the telas (§ 24). The metapore is here represented as an interruption of the metatela. If, as now seems probable (§ 83), it is an evagination, there still remains the difficulty of determining its extent, and the best mode of representing it.

D. For the sake of comprehensiveness certain features are included which do not occur in all vertebrates—*e.g.*: the metapore (in man and a few others); the pons (mammals only); the medicommissure (mammals and some reptiles); the paraphysis (not found in mammals*); the chiasma (absent in teleosts).

E. The dotted areas represent fibrous parts crossing the meson whether directly (precommissure) or obliquely (chiasma); the similar representation of the medicommissure is not warranted by its cellular structure in mammals.

F. Other differentiations of the substance of the parietes are not indicated, *e.g.*, into the alba (white substance) and the cinerea (gray).

G. The hypophysis is notched and crossed by the broken line to indicate its twofold source, neural (*n*) and enteric (*e*) § 146. The ectal line which elsewhere represents the pia enveloping the brain should not be so interpreted for the enteric portion.

H. The indentation of the precommissure merely emphasizes the relations of its two portions to the rhinencephal and the prosencephal respectively (§ 364).

I. The indentation of the mesencephalic roof represents the transverse furrow which—in mammals only—demarcates the quadrigeminum into a pregeminum and a postgeminum; the former, I believe, is always the larger, but the ratio is not known to me. No attempt is made to indicate the intergeminum ("interoptic lobes" of Spitzka).

J. The two indentations of the cerebellum, ental and ectal, represent respectively the fastigium (§ 95) and the furcal sulcus (§ 117), but without implying their exact collocation.

K. The crista has been observed in comparatively few vertebrates and its morphological significance is undetermined (§ 366).

L. *The Absence of Flexures.*—Granted that no brain is perfectly straight and that many are strongly flexed in one or more places, how many flexures shall be represented and what shall be their extent? The only impartial condition of the axis is straight (§ 38).

M. On the same principle the dorsal and ventral outgrowths, paraphysis, dorsal sac (*s.d*), epiphysis, and hypophysis, are made to project nearly at right angles with the brain axis. In many vertebrates the hypophysis tends caudad, but in man it tends rather in the opposite direction, and in the goose-fish (*Lophius*) it lies far cephalad of the rest of the brain.

N. *The Dorsal and Ventral Zones.*—It is conceded that the myel is demarcated by an interzonal sulcus ("*sulcus limitans ventriculorum*" of His) into a dorsal zone which is sensory and a ventral which is motor; also that the sulcus and zones are represented more or less distinctly in the caudal half of the brain. On the figure the sulcus is conventionally indicated by the segmental names, *mesencephal*, etc., and by the three lines connecting them. But I have as yet been unable to satisfy myself of the

TABLE I.—COMPARATIVE VIEW OF THE SEGMENTAL SCHEMAS ADOPTED BY—

THE ANATOMISCHE GESELLSCHAFT IN 1895.	THE ASSOCIATION OF AMERICAN ANATOMISTS IN 1897.
Partes ventrales. *Partes dorsales.*	I. RHINENCEPHALON. Bulbi olfactorii with their tracts, part of the aula and of the precommissure.
VI. TELENCEPHALON. Pars optica hypothalami. Corpus striatum; rhinencephalon; pallium.	II. PROSENCEPHALON. Palliums, connected by part of the aula and part of the precommissure.
V. DIENCEPHALON. Pars mamillaris hypothalami. Thalamus; metathalamus; epithalamus.	III. DIENCEPHALON. Thalami, including the chiasma; genicula.
IV. MESENCEPHALON. Pedunculi cerebri. Corpora quadrigemina.	IV. MESENCEPHALON. Crura and quadrigeminum.
III. ISTHMUS RHOMBENCEPHALI. Pedunculi cerebri. Brachia conjunctiva; velum medullare anterius.	V. EPENCEPHALON. Cerebellum; pons; preoblongata.
II. METENCEPHALON. Pons. Cerebellum.	VI. METENCEPHALON. Postoblongata.
I. MYELENCEPHALON. Medulla oblongata. *Pars ventralis.* *Pars dorsalis.*	

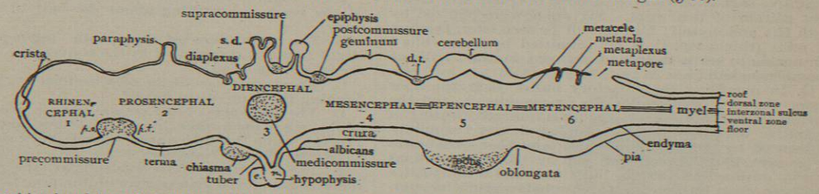

FIG. 675.—Provisional and Imperfect Schema of the Brain as if Medisected; intended to approximate the "least common multiple" of the brains of vertebrates above the lancelet.

Abbreviations:—In the floor, at the sides of the precommissure, *p. o.* designates the olfactory division (*pars olfactoria*) and *p. t.* the cerebral or temporal division (*pars temporalis*) of that commissure. In the hypophysis, *e.* designates the portion derived from the enteron (prehypophysis), and *n.* the strictly nervous portion (posthypophysis). In the roof, *s.d.* designates the dorsal sac (*saccus dorsalis*), and *d. t.* the decussation of the trochlear nerves (*decussatio trochlearis*). The numerals indicate the six definitive segments beginning with the most cephalic (compare Fig. 680).

* This, the "isthmus cerebri" of some writers, must not be confounded with the "isthmus rhombencephali" of others, which includes a portion only of the mesencephalon (see Table I.).

* The callosum and fornix are omitted because their inclusion would have caused undesirable complications.

* See the turtle's brain Fig. 680. The part is briefly discussed by Minot, 1892, 690, and by Studnička, 1893.

continuance of these features in the cephalic half of the brain (see § 153).*

O. Comparisons will be made naturally and justly with (*a*) representations of the primary neural segments or true neuromeres like, *e.g.*, that of Charles Hill (1899, 1900); (*b*) the schema of Prof. Wilhelm His (1893) which was adopted in 1895 by the Anatomische Gesellschaft (His, 1895); (*c*) that of Huxley (1871); (*d*) my own successive attempts, especially that in the first edition of this work, vol. viii., p. 114, which was substantially identical with that in the last four editions of Quain's "Anatomy." From all four it differs in the recognition of the olfactory region of the brain as a definitive segment; from the first it differs also in regarding adult rather than early embryonic conditions—thus in recognizing the final, actual, or definitive segments rather than the primitive or potential neuromeres; from the second, in addition to minor points that may be mentioned later, it differs also in the greater regard for the conditions in the lower vertebrates; in the non-recognition of the "*isthmus rhombencephali*" as a definitive segment; in the method of numerating the segments and in the names of some. See also my papers, 1897, *e*, and 1899, *c*.

P. *The Number of Segments.*—On this point the differences of opinion and usage are wide and radical; my own views have changed more than once and may change again. No one admits more fully the need of further information and of more logical interpretation. The practical question that now confronts us—investigators, teachers, and students alike—is this: In the present state of our knowledge, ignoring no known conditions of the brain, adult or developmental, and assigning at least equal weight to the lamprey and to the hag as to man, what number of transverse divisions shall be recognized, so as to facilitate the exposition and comprehension of the main features of a highly complex organ while not hindering the elucidation of the mysteries as yet unsolved? These divisions must be natural, not necessarily identical but at least comparable, and neither so few as to be useless nor so many as to be inconvenient. The practical requirements are met by the numbers five and six. Five definitive segments were recognized in Quain and in the first edition of this work. Six are now recognized by both His and myself; but, as will be seen later, the first of mine (rhinencephal) is not admitted by him, while I am unable to see a definitive segment in the "isthmus rhombencephali."†

Q. In regarding the olfactory bulbs, their tracts or crura, the *pars olfactoria* of the precommissure, and the corresponding portion of the aula, as constituting a definitive segment, the rhinencephal, I may be unduly influenced by the conditions in certain other vertebrates (Figs. 680, 790, 791, and 794) and by the considerations briefly outlined in 1897, *e*; but I feel that scant justice has been dealt hitherto to this probably primitive portion of the brain.

R. *The Developmental and Structural Disparity of the Segments.*—Whatever number of definitive segments any anatomist admits, he will hardly claim that they are identical in either structure, mode of development, or relation to the primitive neuromeres. According to Charles Hill the mesencephal represents two neuromeres, and there certainly are several in the oblongata.

S. *The Relative Size of the Segments.*—This point is analogous to that respecting the direction of the axis of the entire brain (L). Even were the preponderance of the cerebrum in man and other mammals to be indicated the precise ratio would not be easy to fix. But in some sharks the cerebellum is very large; in Teleosts the mesencephalic lobes are most conspicuous; in *Chimaera* the diencephal is greatly prolonged (W., 1877, *a*); in the electric ray the postoblongata (metencephal) equals in size the remainder of the brain. Finally, to offset the relative insignificance of the olfactory bulbs in the Primates and their total absence in certain Cetacea, they compare favorably with the other segments in many Reptiles and Amphibia, in the hags (Fig. 790) they are as wide as the cerebrum, and in the lamprey (Fig. 789) they surpass it in bulk. There seems to be no escape from the conclusion exemplified in the schema, viz., that the definitive segments are potentially equal in size.

T. *The Numerical Designation of the Segments.*—In accordance with the rule (to which there is, so far as I know, but a single exception*)—viz., that the members of any cephalo-caudal series of similar parts, *e.g.*, ribs and vertebræ, should be numbered beginning with the one next the head—anatomists have hitherto generally designated the segment next the myel as last and the one at the other extreme as first. That plan is adhered to in Fig. 674, and throughout this article. The contrary enumeration was introduced by Professor His in 1893. It has been adopted by the Anatomische Gesellschaft, and there is likely to result confusion such as would attend the reversal of the universal method of enumerating the cranial nerves.

U. *The Segmental Names.*—As may be seen from the table of His reproduced in the latter part of the article *Brain, Development of*, and from the abstract of it in Table I., the most radical differences concern the two segments next the myel. The Association of American Anatomists follows Quain in designating the most caudal *metencephalon* and the next *epencephalon*. The Anatomische Gesellschaft follows Huxley in applying *metencephalon* to the penultimate segment and designating the ultimate by *myelencephalon*.†

§ 46. *Fig. 676 illustrates:* A. The great relative bulk of the head, constituting about one-half of the entire body.

B. The indications of encephalic segmentation by slight furrows, represented by the converging lines upon the side of the head.

C. The prominence of the mesencephal at this period, forming the "top of the head."

D. The sharpness of the cranial flexure, whereby two of the segments appear in a dorsal view, and two in a ventral, while the fifth appears partly in both views, as shown by Figs. 677 and 678.

E. The conditions of the eye and ear; the greater differentiation of the manus than of the pes; the presence of a short but distinct tail.

§ 47. *Fig. 677 illustrates:* A. The distinctness of the myelocele ("central canal") even to the root of the tail.

B. The sudden and great expansion to constitute the metepicele ("fourth ventricle").

C. The marked constriction between the mesocele and the metepicele.

D. The existence, on the contrary, of the greatest

* Burckhardt has represented the zones and other features by an elaborate system of colors; 1895.

† Should the "isthmus rhombencephali" be regarded as a definitive segment? In the early fetal brain of man, the cat, and perhaps some other mammals, there is a neck-like region just caudad of the mesencephal. Professor His names this region "isthmus rhombencephali," and apparently regards it as co-ordinate with the other five segments recognized by him (1893, 173–174; 1895, Suppl. Bd., 157). But these same specimens, and indeed many of the figures of Professor His, present an equally distinct constriction cephalad. Even if the former represents the second of the two neuromeres which Charles Hill credits to the mesencephal, it is not easy to see why one of these regions, so insignificant in the later stages, should be reckoned as a definitive segment rather than the other. This point has been formulated independently by Dr. Stroud in the title of his paper, 1899, *a*, "If an Isthmus Rhombencephali, Why Not an Isthmus Prosencephali?" from which Fig. 671 is borrowed.

* Dr. Gerrish informs me that in the famous work of Albinus, "Tabulæ sceleti et musculorum corporis humani," 1747, the vertebræ, lumbar, thoracic, and cervical, are numbered from the caudal to the cephalic end of each series; nevertheless, curiously enough, the ribs are enumerated in the more usual way.

† Undesirable results or concomitants of the application of *myelencephalon* to the last (most caudal) segment, and of *metencephalon* to the next (cerebellar) segment, are the following: (*a*) Disregard of the prior association of *epencephalon* with the cerebellar segment by Owen and Quain. (*b*) Disregard of Owen's prior application of *myelencephalon* to the entire cerebro-spinal axis. (*c*) Inconsistency, since the *myel* of *myelencephalon* obviously refers to the "spinal cord" which, however, is termed *medulla spinalis*. (*d*) The apparent impossibility of having an appropriate or correlated convenient word term for the cavity of the last segment. *Myelocœlia* (Eng. *myelocele*) was applied by me to the cavity of the myel (canalis centralis); *myelencephalocœlia* would be cumbersome; likewise *ventriculus myelencephalicus*.

width of the metepicele opposite the ventral transverse furrow which is regarded by me as demarcating the cephalic portion (epicele) from the caudal (metacele).

E. The slightness of this transverse depression of the floor. With some human embryos of this and later stages (Fig. 671) there is a marked flexion (the pons flexure) of this entire region, at about the middle of its length, so that the two segments are easily distinguished.

§ 48. *Fig. 678 illustrates:* A. The greater width of the mesocele than of the diacele, so that the latter might be described as merely a passage between the former and the prosocele.

B. The absence of any distinct thickening of the diacelian walls to indicate the formation of the thalami.

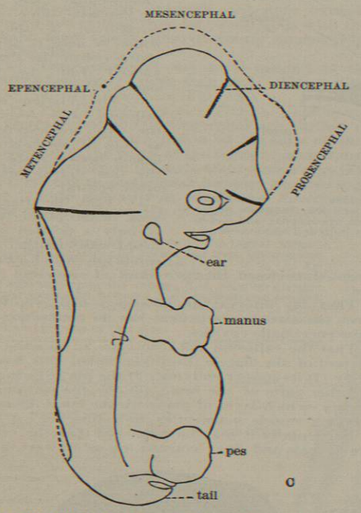

FIG. 676.—Right Side of a Human Embryo, 18 mm. long, and Estimated to be Four Weeks of Age; 274. × 6.
Preparation.—The embryo was received in its membranes, and had apparently lost much of the neck curvature, so that the head is more nearly than usual in line with the body. The encephalic cavities were exposed by removing their roofs; the original outline is indicated by the broken line.

C. The mesal depression in the diacelian floor, probably representing the infundibulum.

D. The lateral extension of the paraceles, the cavities of the future hemicerebrums.

E. The presence of an elevation of the paracelian floor, probably representing the caudatum.

F. The continuity of the parietes at the junction of the prosencephal with the diencephal, and the absence of any indication of plexal intrusion at this period.

§ 49. *Commentaries upon Fig. 679.*—A. This figure is a combination of parts of Figs. 677 and 678, as if the encephalic curvature were obliterated. This ideal straightening, a form of normalization (§ 38), may be illustrated as follows: Flex the index finger upon itself as far as possible; let the nail represent the prosocele, the knuckle the metepicele, and the prominent middle joint the mesocele. From either the dorsal or palmar aspect only parts of the convex surfaces are visible; but if the finger is extended all fall into one view.

B. The main object of this figure is to facilitate a comparison between the encephalic cavities of this early embryo and those of the adult cat as shown in Fig. 686. The differences are much greater in appearance than in

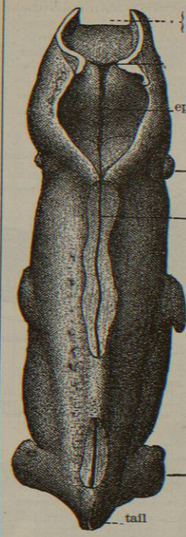

FIG. 677.—Dorsal Aspect of the Embryo Shown in Fig. 676; 274. × 6. This and three of the following figures (678, 679, 681) are too deeply shaded. See § 47.



FIG. 678.—Ventral Aspect of the Embryo Shown in Figs. 676, 677, and 679; 274. × 6. The left arm has been removed. See § 48.

reality, consisting mainly in the reduction of most of the cavities, the thickening of most of the parietes; the great and irregular extension of the lateral masses, hemicerebrums, containing the paraceles ("lateral ventricles").

C. The resemblance of this figure to the appearance presented by the brain of *Necturus* (a salamander) after the removal of the roof is almost startling; see my paper, 84, *a*.

§ 50. The adult human brain presents great and perhaps peculiar departures from the general type as based upon embryology and comparative anatomy, and while anatomically admirable and physiologically nearly perfect, it may fairly be characterized as a morphological monstrosity. Among other general features, the segmental constitution of the organ is more apparent in many lower or more general-

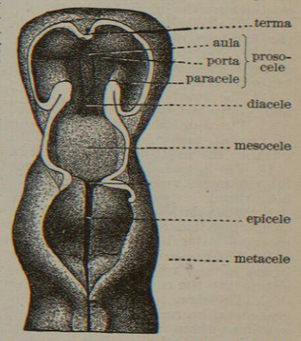

FIG. 679.—The Encephalic Cavities of the Embryo Shown in Figs. 677 and 678 Represented upon One Plane.

ized vertebrates, *e.g.*, the turtle (Fig. 680) and the hag (Fig. 782), and even in mammals where the cerebrum is less preponderant than in man. But with mammals the other segments are more easily recognized if the cerebrum and cerebellum are either tilted in opposite directions as in the rabbit preparation (Fig. 681), or the former is also medisected as in the cat (Fig. 682), or both partly cut away as in the sheep (Fig. 794).

§ 51. *Fig. 680 illustrates:* A. The availability of this reptilian brain for the exemplification of certain features of the organ; it is large as compared with that of amphibia and most other reptiles; the cerebrum and cerebellum do not overtop the other parts so as to obscure their serial relations; excepting the pons and callosum most of the commissures are represented; and the cranial flexure is slight (Fig. 671).

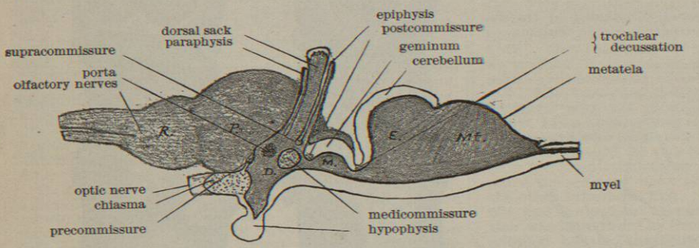

FIG. 680.—Mesal Aspect of the Medisected Brain of the Green Turtle, Chelone midas. × 1. From nature and from the paper of O. D. Humphrey, 1894. The letters R., P., D., M., E., and Mt., designate respectively the six segments, rhinencephal, prosencephal, diencephal, mesencephal, epencephal, and metencephal. The first and second are placed on the pial surfaces of the olfactory bulb and hemicerebrum; the other four are within the cavities.

B. The departure from the schematic brain in two respects: (*a*) the reduction of the mesal portion of the rhinocele and prosocele to a slight cavity, the aula, opening laterad by the porta; (*b*) the crowding of the cephalic segments caudad, occasioning the diencephalic flexure, and bringing the aula and porta dorsad of the diacele instead of cephalad of it.

C. The elongation and close apposition of the three dorsal outgrowths, paraphysis, dorsal sack, and epiphysis.

D. The relatively large size of the olfactory bulb, and the duplicity of the olfactory nerve.

§ 52. *Fig. 681 illustrates:* A. The greater obviousness of the segmental constitution than with the adult human brain from any point of view.

B. The smaller relative size of the cerebrum than in man or the cat (Fig. 682).

C. The much less extent of the callosum than in man or the cat, making it possible to uncover the diencephal without the medisection required in the cat (Fig. 682).

D. The presence of a distinct roof of the diacele, the interthalamic space, notwithstanding the cerebrum has been tilted.

E. The relation of this roof, the diatela, to the habenas, the ridges demarcating the dorsal and ectocelian from the mesal or entocelian surfaces of the thalami.

F. The non-adhesion of the thalamus to the hemicerebrum in any way such as to indicate that the former enters into the composition of the paracelian floor.

G. The more nearly equal size of the lateral (pileums) and mesal (vermis) lobes of the cerebellum, and the concomitant absence of the vallis which is so obvious on the caudal aspect of the adult human cerebellum (Figs. 672 and 697).

§ 53. *Fig. 682 illustrates:* A. The possibility, even with so high a mammal as the cat, of making a preparation that, without disturbing the essential morphological features of the organ, may exhibit portions of all of the encephalic segments excepting the last, the metencephal.

B. The tendency of three of the encephalic segments to overlap those caudad of them. The cerebellum, the epencephalic roof, partly conceals the postoblongata, metencephal, in its natural attitude; in the present figure it is tilted caudad. The mesencephal (gemina or optic lobes) is covered partly by the cerebellum and partly by the cerebrum, and also at the sides overlapped somewhat by the postgeniculums, elements of the diencephal; in the figure these bodies are in deep shadow, crossed by the line 3 on the right, and on the left by the line leading to the postgeminum. Finally, the cerebrum conceals the diencephal and mesencephal, part of the rhinencephal, and even the cephalic slope of the cerebellum in the cat, while in man it alone is visible when the brain is viewed from the dorsal aspect (Fig. 664).

C. The relations of the callosum and fornix to the two hemicerebrums, as lines of secondary adhesion between the two, the one dorsal and the other ventral.

D. That the triangular area, hemiseptum, is really only a portion of the mesal wall of either hemicerebrum, which has been intercepted between the two lines of junction above named.

E. That the interval, pseudocele ("fifth ventricle") between the two hemiseptums, has no connection with the true encephalic cavities.

F. That the callosum and fornix are in no sense parts of the roof of the diacele (third ventricle): this is constituted by (1) its proper endyma, (2) the pia covering this, as all other parts of the brain, (3) the pia pertaining to the fornix, which layer of pia, with the layer (2) and the intervening vessels, constitutes the velum.

G. Incidentally it may be remarked that the cruciate fissure in cats and dogs constitutes, as it were, a gash across the mesal margin near the cephalic end of the hemicerebrum; it appears, therefore, upon both the mesal and the dorso-lateral aspects. The well-known and easily experimented-upon motor areas of the limbs occupy the U-shaped gyre between the cruciate and coronal fissures. It does not follow, however, that the cruciate fissure and the human central fissure are homologous (§ 303).

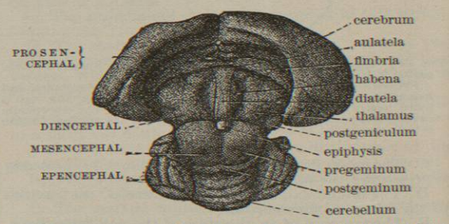

FIG. 681.—Dorsal Aspect of the Brain of a Young Rabbit, the Cerebrum and Cerebellum Pushed in Opposite Directions.
Preparation.—While fresh, the cerebellum was tilted caudad and the hemispheres cephalad, and the velum removed; the brain was then placed in strong alcohol so as to retain the desired shape. The segmental names are at the left, the names of parts at the right. The specimen has been lost or destroyed.

§ 54. *Relative Size of the Segments in the Embryo and the Adult.*—In the embryo at one period the mesencephal is the most prominent region, and it remains the largest in some fishes; in the adult human brain it is one of the least conspicuous.

§ 55. *Segmental Overlapping.*—Although originally subequal in size, certain segments early manifest a tendency to extend beyond their neighbors in one or more directions. In man and the mammals generally this overlapping is in inverse ratio to the original size of the parts. The mesencephal, at one period most prominent, is encroached upon by the diencephal at the sides, by the pons ventrad, the cerebellum dorsad, and all are eventually covered by the cerebrum, primarily a comparatively insignificant portion of the brain.

§ 56. This segmental overlapping is, upon the whole, greater caudad than cephalad, most of the segments presenting something like the "rake" of the mast of a ship. The cerebellum, for example, not only extends both cephalad and caudad from its connections with the epencephalic floor, but is tilted distinctly caudad (Figs. 670, 687, and 693).

§ 57. Transections at any level caudad of the aula usually affect two or more segments. This is illustrated in the following diagrams (Fig. 683).

§ 58. *The Caudato-thalamic Fusion.*—The relations of the prosencephal to the diencephal are further complicated by the intimate fusion of the sides of the latter (thalami) with the floors of the former (caudatums). Although, therefore, in the early embryonic stages (Fig. 671) it is very easy to distinguish between the two segments, there is some difficulty in the adult. For convenience, in the present article, the capsula ("internal capsule") is adopted provisionally as the boundary, so far as regards the thalamus and the lenticula (part of the striatum). But the same medullary stratum intervenes between the lenticula and the caudatum, both prosencepalic parts, and the whole subject requires further elucidation.

§ 59. *The Segments Primitively Mesal and Single.*—This view is generally accepted with regard to the diencephal and the parts caudad of it on account of the familiar conditions of early development. The prosencephal likewise, although commonly described as a pair of lateral masses, is single in "fishes" (see the figures and statements in connection with that segment, §§ 158–162).

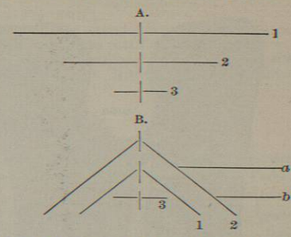

FIG. 683.—Diagrams Illustrating the Lateral Overlapping of the Mesencephal by the Two Segments Cephalad of It. The transverse axes of the prosencephal, diencephal, and mesencephal are indicated by the lines 1, 2, 3, respectively; in A they are directed laterad, as in the early embryonic stages; at B they are inclined caudad, and transections at *a* or *b* would cut two or three segments instead of one.

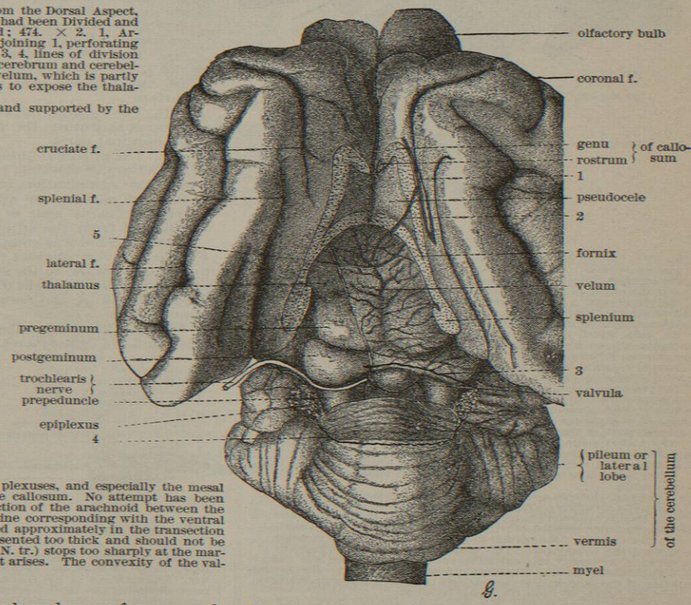

FIG. 682.—The Brain of a Cat from the Dorsal Aspect, After the Callosum and Fornix had been Divided and the Hemicerebrums Divaricated; 474. × 2. 1, Artery (precerebral?); 2, artery joining 1, perforating the callosum from the velum; 3, 4, lines of division of the arachnoid, between the cerebrum and cerebellum; 5, line of division of the velum, which is partly removed on the left side so as to expose the thalamus and gemina of that side.
Preparation.—While fresh and supported by the *basis cranii*, the hemicerebrums were carefully separated so as to expose the callosum; this was divided, beginning with the splenium; then the fornix until the incision reached the point of attachment of the velum. The cerebellum was tilted caudad and the arachnoid between it and the postgeminum divided; the cerebellar edge of the arachnoid is represented by the line 4. The valvula is shown as if inflated with air. On the left side, along a line (5) extending obliquely caudo-mesad from under the margin of the fornix, the two layers of pia constituting the velum were divided, and the part at the left removed so as to expose more distinctly the postgeminum, pregeminum, and thalamus. The cerebral pia was removed. A similar preparation of the human brain is very desirable, but difficult to make, on account of the weight of the cerebrum.
Defects.—The arteries should have been injected with a red mass, for the better exposition of the pia, the plexuses, and especially the mesal artery (2) which penetrates the callosum. No attempt has been made to show the lines of reflection of the arachnoid between the two hemicerebrums, along a line corresponding with the ventral margin of the falx and indicated approximately in the transection (Fig. 732). The fornix is represented too thick and should not be dotted. The trochlearis nerve (N. tr.) stops too sharply at the margin of the valvula, from which it arises. The convexity of the valvula is too sharply defined.

The case of the rhinencephal is less readily disposed of, and will be stated in connection with that segment (§ 370).

§ 60. *Potential Triplicity of the Encephalic Segments.*—Although primarily mesal and simple, each segment presents at some period and in some vertebrates a dis-

tinctly threefold condition, with one mesal and two lateral portions. The prosencephalic triplicity is exhibited in all air-breathing vertebrates and some aquatic

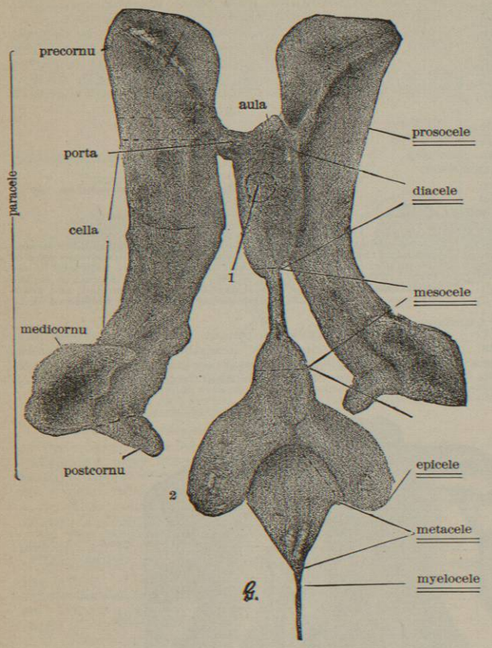

FIG. 684.—Cast of the Encephalic Cavities, Ventral Aspect; approximately correct. × 1 (?) (From Weisker, modified.) The names at the right, doubly underlined, designate five divisions of the encephalocele, together with the slender myelocele (central canal of the spinal cord). The metacele and epicele together constitute the "fourth ventricle" of the text-books; the mesocele corresponds to the aqueduct or iter; the diacele equals the "third ventricle" less the aula, which is the mesal part of the prosocele; prosocele includes all not already specified, viz., the mesal aula, the lateral paraceles ("lateral ventricles"), and the two portas through which they are continuous. The names at the left designate the parts of the paracele, viz., the cella, extending caudad from the porta; the precornu, extending cephalad; the medicornu, extending in a spiral direction laterad, ventrad, cephalad, and mesad, successively; and the postcornu projecting caudad from the cella. 2 is placed near the tip of the right lateral recess of the epicele. The larger part of the figure is modified from a photograph of the wax model made by Weisker, of Freiburg. The metacele, myelocele, and part of the epicele are from a cast of the cavities in a child. The ventral aspect was chosen in order to display to better advantage the uninterrupted series of mesal cavities, and the portas.

Defects.—I doubt whether any part represents the corresponding cavity accurately. The portas are too long (compare Fig. 718). The diacele presents neither the orifice for the medicommissure (the presumed location of which is indicated by the dotted circle (1) just caudad of the portas) nor the marked ventral extension toward the hypophysis. The medicornua are not sufficiently curved; in reality the extremity of each approaches the diacele within about 2.5 cm.; the postcornua are too short; the boundaries of the epicele are vaguely and perhaps incorrectly indicated, and the lateral recesses (2) should be longer.

forms (Dipnoans, etc.); with birds and frogs the mesencephal is markedly tripartite (Fig. 682); with man and other mammals, and likewise with some other vertebrates, the epicele presents more or less extensive "lateral recesses" (Figs. 669, 684, 698). The embryonic diencephal protrudes at either side an optic vesicle that becomes the retina and optic nerve.

§ 61. *Fig. 684 illustrates:* A. The continuity, general form, and relative size of the several divisions of the adult human encephalocele, as viewed obliquely from the ventro-dextral aspect.

B. The obvious triplicity of the prosocele, and the existence of lateral extensions of the epicele.

C. The slenderness of the mesocele as compared with its relative size in the embryo (Fig. 680) and in the adults of some other vertebrates (Fig. 685).

D. The general modifications of the primitive and typical condition of the encephalic cavity which led the older anatomists, and still lead some of their modern successors, to regard the whole as comprising four "ventricles," a first and second (lateral), a "third," and a "fourth," the aula being ignored and the mesocele considered merely as a "passage from the third ventricle to the fourth."

§ 62. *Fig. 686 illustrates:* A. An arrangement and circumscription of the encephalic cavities in the adult cat (an accessible mammal), essentially identical with that in the human adult (Fig. 735) and fetus (Fig. 716), and in vertebrates generally.

B. The great differences in size and shape between the various divisions of the encephalocele; the mesocele is little larger than the myelocele, and is tubular; the diacele is narrow but high; the metacele wide but shallow; the epicele is very irregular; the myelocele is patent throughout, while in man it is nearly obliterated. The epicelian lateral recesses are not exposed, so the triple constitution of a typical segmental cavity is exhibited only by the prosocele, with its mesal, aula, and lateral paraceles.

C. The different constitution of the celian parietes. The roofs of the aula, portas, and metacele are membranous telas, with plexuses on the ental surface.

D. The reduced thickness of the parietes near the rima, constituting the fimbria, one of the riparian or marginal parts.

E. The apparent interruption of the wall of the medicornu at the rima ("great transverse fissure"). On close examination, however, although the proper nervous parietes are absent, the intruded pial fold (paraplexus) is seen to be covered by the endyma reflected from the adjoining parts, so that the injected alcohol was completely confined.

F. The not very obvious relation of the ectal furrow, hippocampal fissure, to the ental elevation or colliculus, hippocamp; on the right the line from *postgeniculum* crosses the end of the fissure, which is not otherwise indicated.

G. The relations of the alba (medulla) to the ectocinerea (cortex) and the entocinerea ("central tubular gray");

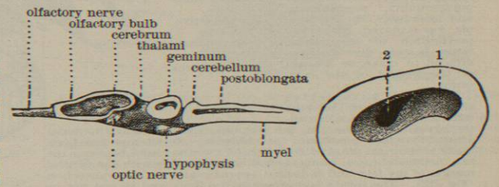

FIG. 685.—Left-hand figure: Brain of Frog Seen from the Left After Removal of Parts of the Left Side; 654. × 1.5. Right-hand figure: Enlargement of the Geminum (Mesencephal), so as to show more distinctly the lateral cavity of the mesocele and the orifice (comparable with the porta) by which it communicates with the mesal cavity.

the metepencephalic entocinerea has been removed in exposing the cavities, but it is distinct and abundant at the sides of the mesocele (aqueduct), of the diacele, constituting the thalamus, and of the prosencephalic precornu, constituting the caudatum and—unexpectedly—the hemiseptum and column of the fornix, all which were distinctly gray in the fresh preparation.

H. The caudal extension of the cerebrum so as to reach the cerebellum, and thus conceal the lateral aspect of the intervening segments, diencephal and mesencephal.

I. The fusion of the thalamus with the caudatum, of the diacelian side wall with the paracelian floor. The line of junction of the two segments may be regarded as indicated approximately by the word *dien*.

J. The absence or inconspicuousness of the lenticula, claustrum, and insula (compare Fig. 782).

K. The less width of the diencephal than in man, so that the geniculums maintain their proper morphological relation of cephalic (pre) and caudal (post), rather than of lateral, or "external," and mesal, or "internal," as in man.

L. The extension of the paraceles, the proper cavities of the hemicerebrums, caudad from the aula even farther than cephalad, thereby warranting the diagrammatic representation of the paraceles as lateral extensions, not cephalic only.

M. The absence of a postcornu in the cat as in most other mammals, the exceptions being man, monkeys, seals, porpoises, and some dogs.

N. The distinctness of the crista in the cat. It is not named on the figure, but may be seen as a conical elevation at the cephalic side of the aula; the line from *aula* points at it.

§ 63. *Celian Circumscription.*—The facts of development and comparative anatomy, and analogy with other hollow organs warrant the presumption that the encephalic cavities communicate only with one another and with the myelocele. Any communication with the ectal surface is presumably artificial, excepting, perhaps, at the metapore ("foramen of Magendie") and the lateral recesses (§§ 78, 98).

§ 64. *Endymal Continuity.*—The endyma is the essential and absolutely constant constituent of the celian parietes; hence in all figures purporting to illustrate celian circumscription the line representing the endyma should be distinct and uninterrupted, excepting where discontinuity has been demonstrated.

§ 65 *Fig. 687 illustrates:* A. The sharpness of the cranial or mesencephalic flexure in man. Compare the sheep (Fig. 794) and the turtle (Fig. 680).

B The continuity of the endyma lining the mesal series of cavities excepting at the metapore, and the concomitant completeness of the celian circumscription.

C. The non-communication of the pseudocele with the true cavities. (The meninges and blood-vessels are considered under Fig. 801.)

§ 66. In tracing the continuity of the endyma at the meson it is best to begin with a region where a rupture could hardly occur in either floor, roof, or sides, and where also a transection is most readily effected when

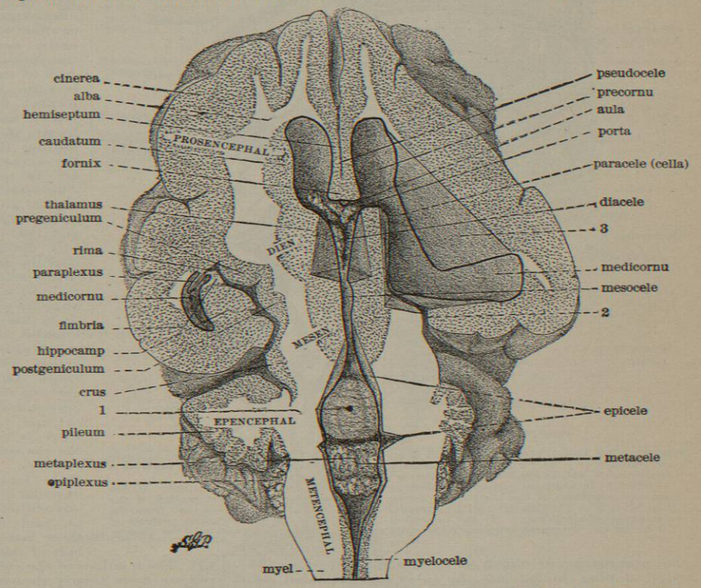

FIG. 686.—The Encephalic Cavities of a Cat, Exposed from the Ventral Side; 479. × 2. 1, The valvula, which is so thin in the cat that the cerebellar folia show dimly through it (the line is interrupted just above the L of EPENCEPHAL); 2, the narrow space between the lateral aspect of the mesencephal and the overlapping hemicerebrum; in anthropotomy this is commonly reckoned as part of the "great transverse fissure"; 3, obliquely cut surface, left by the removal of the caudatum and adjacent parts of the left hemicerebrum.

Preparation.—The brain was exposed from the ventral side and left in the calva for better support. the cavities were alinjected so as to harden the parietes and keep them apart. Successive slices were removed until the portas and aqueduct (mesocele) and myelocele were exposed. With a narrow-bladed knife the walls of the diacele (including the medicommissure), epicele, and metacele were cut away obliquely; also on one side (the right of the preparation, but the figure is reversed so that it appears on the left) the caudatum, hippocamp, and part of the thalamus, so as to expose the continuity of the precornu and medicornu. The olfactory bulbs were removed with the ventral portion of the cerebrum. The boundaries of the cinerea (cortex, etc.) and alba (medulla) were ascertained by comparing the similarly exposed surface of a fresh brain; some of the differences between the two sides are due to a slight difference of the section-levels.

Defects.—The brain should have been prepared in a chromic-acid solution, or injected with the red mixture, so as to differentiate the alba and cinerea.

the entire brain is to be studied in two parts, a cerebral and a cerebellar portion. This "place of election" is the mesocele ("aqueduct" or "*iter a tertio ad quartum ventriculum*").

A. The endyma covering the floor of the mesocele may be traced caudad (actually almost directly ventrad) with slight depressions and elevations through the oblongata to the myel where it lines the slender myelocele, the "canal of the cord."

B. Recommencing at the same point in the mesocele, the floor endyma turns quite sharply ventrad over the cephalic curvature of the crus, passes the albicans, and reaches a region where the floor is thin and frequently