

nucleus sheath; agreeably aromatic, and of a pungent, warm taste." When ginger is not peeled it has a grayish or brownish wrinkled surface. Inferior and dark-colored grades are sometimes bleached with sulphur, chlorinated lime, etc., or are even "whitewashed" with chalk and water, or some such mixture, to give them a whiter and more salable appearance. This treatment also protects them against the attacks of insects. The relative commercial and medicinal values of ginger do not agree. For medicinal purposes it is better with the very active rind left upon it, but its commercial value depends more upon its ability to yield a clear, light-colored preparation, which is true of the peeled articles. The principal varieties in the order of their estimation are Jamaica, Cochín, and African. The last, though the cheapest, contains the largest amount of active constituents, and is to be preferred for medicinal use.

**COMPOSITION.**—Ginger contains a pale yellow volatile oil to the extent of about one or two per cent., having its odor and taste without its pungency. The remaining constituents are a composite resin, besides the real source of its pungency, gingerol, which, however, is not volatile or aromatic. Twenty per cent. of starch, fat, gum, and various amorphous and uninteresting substances make up the rest. The oil and resins are contained in cells resembling those of the parenchyma, and irregularly scattered among them. The ethereal extract (*Oleo-resina Zingiberis*, U. S. P.) is composed of these resins in combination with the essential oil, fat, etc., and is yielded by different varieties to the extent of five to ten per cent.

**ACTION AND USE.**—Ginger is a spice more aromatic and less pungent than pepper, and, like others of its class, in suitable dose is gently stimulating to the stomach and intestines, and in its way a carminative tonic. In large doses it is irritating; locally applied to the skin it is rubefacient to a less degree than mustard, and useful where a mild counter-irritation is desired. It is used in colics, atonic dyspepsia, flatulence, etc., and is a favorite flavor for cakes, drinks, and preserves.

**ADMINISTRATION.**—In powder the dose may be taken as from 0.5 gm. to 1 gm., usually mixed with other aromatics. An infusion, under the name of "ginger tea," is a favorite preparation in the country. A fluid extract is official (*Extractum Zingiberis Fluidum*, U. S. P.), but not much used. The tincture (*Tinctura Zingiberis*, U. S. P.) is in universal employment; its strength in this country is twenty per cent. The oleoresin or ethereal extract (*Oleo-resina Zingiberis*, U. S. P.) is a very concentrated form suitable to add to pills and boluses. Dose, a decigram or so. The official syrup contains three per cent. of the fluid extract, and the troches each about three minims of the tincture, with a little of the syrup. Ginger also enters into the compound rhubarb powder and the aromatic powder, both official.

A little of the preserved ginger of the shops makes a delicious and wholesome addition to the meal.

The alcoholic preparation popularly sold under the name of "Jamaica Ginger" is used to some extent, especially in mining communities, as an intoxicant. The cerebral effects have not been suitably studied, but are markedly distinct from those of ordinary alcoholism, there being narcotic effects apparently due to the ginger itself. A number of cases of blindness may be due to the employment of methyl alcohol. *Henry H. Rusby.*

**GINGER, OIL OF.**—This is an article of commerce, possessing the odor and flavor, but not the pungency nor full physiological effects, of ginger. It is pale yellow, with a specific gravity of 0.880 to 0.885, and contains camphene as one of its active parts. *Henry H. Rusby.*

**GINSENG.**—A name applied to the roots of several species of *Panax* L. highly prized in superstitious Chinese medicine, and chiefly so used, though they have some mild aromatic properties (see *Araliaceae*). The original Ginseng ("Schin-Seng") is *P. Ginseng* C. A. Meyer, of China, never seen in commerce here. The American

variety, from *P. quinquefolium* L. (*Aralia* q. Deene), is chiefly exported to China and is bought eagerly, at high prices, by Chinese merchants for that purpose. It used to be very abundant in rich forest lands of the Eastern United States, but has been largely exterminated, except in remote sections. It is of very slow growth and, when well developed, presents two principal branches, and occasionally a small intermediate one. From this peculiar form, it is regarded as effective in determining the sex of the unborn child, whence its high repute in China. It contains considerable gum and starch and a little volatile oil and resin and the peculiar, but apparently inert, sweetish substance *Panaquilon*, soluble in alcohol and water. Obviously, there is no dose for so inactive a drug. *Henry H. Rusby.*

**GLANDERS.**—An infectious disease caused by the *Bacillus mallei* and characterized by foci of inflammation, often assuming nodular form, in the skin, subcutaneous tissue, muscles, and lungs. The disease is most commonly found in the horse; the cases in man arise by infection from the horse or some member of the Equidae. According to Hecker,<sup>1</sup> the disease was first described under the name malleus in the fourth century. The first reliable observation of the disease in man was made by Schilling in 1821, and this was followed in 1837 by a monograph by Rayer<sup>2</sup> on the human form of the disease. The idea that the disease was contagious was held by all the early writers, and it was not until 1749 that Lafosse<sup>3</sup> affirmed it to be a spontaneous disease not transmitted by contagion. In 1840 the contagiousness of the disease was definitely established by animal inoculation.

The *Bacillus mallei* was discovered by Löffler and Schütz<sup>4</sup> in 1882. They isolated the bacillus in pure cultures, and by animal inoculations proved that it was the cause of the disease. The bacillus is slightly curved, not quite so long as the *Bacillus tuberculosis*, but somewhat thicker than this. The ends are rounded. It is non-motile in fluid cultures. It is a facultative anaerobe. In old cultures various involution forms are seen. The bacilli may grow out to long rods with irregular swellings along them, or they may form chains of small granules resembling cocci. In cover-glass preparations made from the lesions the bacilli usually appear somewhat longer and thicker than the tubercle bacilli, and show numerous sharply defined, clear, or faintly stained areas in their protoplasm. According to Csoker,<sup>5</sup> there are five pale and five dark points in each bacillus. They grow readily on most of the culture media, and have a characteristic growth on potato. On potato, after thirty-six hours in the incubator, a rather thick, colorless viscid growth appears which soon assumes a brownish tint and resembles honey in appearance. Later, the brown color changes to a dark reddish-brown, and the growth becomes thicker and more opaque, while the potato takes on a dark gray color. No other organism produces on potato exactly the same growth. The bacillus of glanders is one of the most easily destroyed of all the microorganisms, and to this is probably due the relative infrequency of the disease. In pure cultures the bacilli die usually at the end of a few weeks, and they lose their virulence by the eighth day. Being vegetative forms only, heating to 55° or 60° C. for a few minutes destroys them. They are destroyed in the pus in forty-eight hours, when this is dried in a thin layer, and under the best conditions they will not stand drying more than three weeks. They are also very susceptible to the action of germicides. The bacilli are decolorized by the Gram stain. They easily stain in the basic aniline colors, but are easily decolorized. In sections they may be stained by Löffler's solution, but are less intensely stained than the nuclei of the cells. From the impossibility of staining them intensely it is often difficult to demonstrate them in tissues even when they may be present in considerable numbers.

A substance to which the name mallein is given is obtained from cultures of the bacilli. When this is injected into an animal affected with glanders in any form

a characteristic reaction is produced which is diagnostic. This substance was prepared in 1888 by Helmen, a Russian veterinarian. Its diagnostic value was first demonstrated in 1891 by Kalming, of Dorpat, who became infected with the bacilli in the course of his laboratory experiments, and died of glanders.<sup>6</sup> Since this time its use as a diagnostic agent has become general. The mallein is obtained by the sterilization and filtration of a virulent culture of the bacilli in glycerin bouillon. The culture should be one month old. The filtrate is then evaporated to one-tenth of the weight of its volume, which gives a brownish syrupy fluid, and this is diluted ten times with one-half-per-cent. solution of carbolic acid. The dose is 0.5 cm. of the undiluted, or 5 cm. of the diluted solution. When this dose is injected subcutaneously into a healthy horse no reaction is produced. In a horse with glanders the injection is followed by extensive oedema of the subcutaneous tissue around the point of injection, chills, and an elevation of temperature which begins some hours after inoculation, reaches 3-4° C. above normal in twenty-four hours, and persists for several days. The method is especially important in making possible the diagnosis of latent glanders in which no lesions are evident. It is absolutely sure as a means of diagnosis when certain precautions which have been formulated by Nocard<sup>7</sup> are observed. The reaction can be considered typical only (1) when there is fever of from 1 to 5 degrees Centigrade; (2) when there is a large, hot, sensitive oedematous swelling around the point of injection; (3) when there is a general affection shown by weakness, loss of appetite, and muscular trembling. If there is no reaction, it is proof that the animal is not affected. It is necessary to see that the animal has no fever at the time and that afterward it is not exposed to weather conditions which may affect the temperature. In some of the animals which show the reaction there may be very insignificant lesions consisting only of a few small nodules in the lungs.

McFadyean<sup>8</sup> considers the local reaction of the most importance and sufficient alone for the diagnosis. In healthy horses there may be a slight local reaction, but the swelling is rarely more than three inches across and reaches its acme in from fourteen to sixteen hours. In infected horses the swelling is rarely under five inches across, often twice this, and continues to increase for twenty-four hours.

The ass is the most susceptible to natural infection, and the disease assumes a more acute form in this animal than in the horse. The mule is also more susceptible than the horse. Field mice are very susceptible, while white mice and rats are immune. Cats, guinea-pigs, squirrels, and rabbits are all susceptible in the order named; sheep and goats are less susceptible; dogs, birds, with the exception of the dove, beef cattle, and hogs are immune. Natural infection is very rare except in the Equidae and in man. Lions and other carnivorous animals in menageries have been infected by feeding on the flesh of glandered horses.

In the horse various forms of the disease may be recognized, dependent upon its situation and acuteness of course. In the acute form the period of incubation is short. The disease begins with intense fever preceding all local manifestations. The prostration is extreme, the animal is insensible to excitation, locomotion is painful, the hair is rough, and there are muscular twitchings of the shoulders and chest. Appetite disappears completely, cold water is drunk greedily, and emaciation is rapid and extreme. According to Nocard,<sup>9</sup> the loss in weight may be more than 20 kgs. in twenty-four hours. These primary symptoms give place in from one to three days to the specific local symptoms. The lesions are in the mucous membranes and skin. The mucous membrane of the nose is intensely reddened or often of a violet tinge, and small ecchymoses may be seen. An abundant secretion flows from the nostrils; at first it is thin and watery, but later it becomes muco-purulent and often contains streaks of blood. In the swollen mucous membrane small pustules appear which open and give rise to small shallow ulcers,

with raised edges and a bright red base. These ulcers rapidly enlarge, they become confluent and give rise to large irregular ulcerated surfaces covered with muco-pus. The ulcers are sometimes formed by the rupture of oedematous areas beneath the surface. In these areas extensive destruction of tissue seems to take place without any reaction, the softening finally extending to the surface. When the ulceration is advanced the nasal discharge is very abundant and contains fibrinous coagula and portions of necrotic tissue. While these lesions are taking place in the mucous membranes, hot painful tumors appear in various places, especially on the extremities, the flanks, and the shoulders. The oedema about them disappears, leaving hard, solid nodules which ulcerate rapidly. The ulcers become confluent, forming large irregular surfaces which produce an abundant, thin, odorless, often bloody pus. A similar infiltration extends along the course of the neighboring lymphatics, leaving hard cord-like swellings which ulcerate at various points and form thinner chains of ulcers uniting the larger. The lymph nodules belonging to the affected regions become swollen and indurated, finally breaking down into abscesses. The disease owes its name to the frequency with which the affection involves the lymph nodes (lymph glands). During this period the temperature continues high, often reaching 42° C. The loss of appetite and emaciation continue, there appear evidences of occlusion of the nasal respiratory passages, and at the last either general oedema of the lungs makes its appearance or foci of pneumonia develop. The acute form of glanders is always fatal, the disease lasting from eight to thirty days.

The chronic variety of the disease does not take the definite course of the acute, and may assume a number of forms which differ so much from the one from the other that they have been regarded as different diseases. Thus the skin lesions have been considered a separate disease under the name of farcy. In the two classic types of the chronic form the predominant lesions are found in the one in the skin, and in the other in the mucous membranes and parenchymatous organs. The chronic lesions are of the same general type as the acute, their evolution is much slower, and their special characteristics are better marked. The first lesions to appear in the skin are the hard nodules (farcy buttons) followed by ulceration. Hot, painful, oedematous tumors appear in various places in the subcutaneous tissue, especially where the skin is thin and the subcutaneous tissue abundant. These tumors may be the size of a nut or of an egg. Gradually they become smaller in size by the absorption of fluid, and the central mass becomes hard and definitely circumscribed. The hair falls out, the skin becomes thinned, and finally an abscess is formed which contains a viscid yellowish liquid streaked with blood. The opening does not close, and the abscess gives rise to an ulcer. The edges of this are elevated and covered with thick granulations. The ulcer may extend laterally or in depth, both by continuous extension and by the formation of neighboring nodules which follow the same course and finally unite with the main ulcer. The skin in the vicinity is hard and indurated. The ulcers may finally cicatrize. The same swelling which preceded the formation of the nodules and ulcers extends along the subcutaneous lymphatics. The acute swelling subsides, leaving a hard cord (farcy pipe). A number of lymphatics may be affected, giving rise to a network of cords. These may persist for a long time without change, or in some cases nodular swellings appear along them at intervals, and these nodules may soften and ulcerate in the same way as the nodules first described. The ulceration may extend between adjoining foci along the course of the vessel and in this way large irregular ulcerated tracts may result. The lymph nodes are swollen and become finally converted into hard, indurated, adherent masses. They rarely soften and give rise to abscesses as in the acute cases.

The specific affections of the nose are very similar to those in the skin, with differences due to the different character of the tissue. They consist in the formation of

nodules and in ulceration which may terminate in extensive cicatrization. The nodule is preceded by a diffuse swelling of the tissue. The nodules are round, hard, and




FIG. 2298.—Stellate Cicatrix from Nasal Septum. From a case of chronic glanders. (Kitt.)

much smaller than those of the skin. The centre softens and is discharged, leaving a shallow irregular ulcer with elevated edges. Large irregular ulcers are formed by the union of adjoining ulcers. The edges are hard and indurated, and cicatrization is often found in one part while the ulcer is extending in another. Dense white radiating cicatrices are found, and these are the most characteristic lesions of the disease (Fig. 2298). The ulcers may extend in depth, both cartilage and bone may be destroyed, and perforation of the septum may be produced. The nasal discharge varies in character and amount, depending on the character of the lesions. It is more abundant while the animal is at work. In the beginning of the process it is thin and watery, but later it becomes

mucopurulent. In some cases a lymphatic fluid is discharged which coagulates on exposure. When the ulceration is marked it may contain necrotic tissue, and when large vessels are opened by the extension of the ulcers there may be epistaxis. The lesions in the lungs which may be very extensive, do not give rise to any characteristic symptoms. There may be cough and evidence of respiratory trouble, and when the pleura is involved in the process there may be the physical signs denoting this.

In addition to these more common conditions of chronic glanders there are others which are only occasionally met with. A diffuse swelling of the subcutaneous tissue, at first hot and painful, later indurated and contracted, much resembling the nodule in its general features, may take place. The induration becomes brawny and may ulcerate at several points. In stallions swelling of the testicle is often seen and may form the first symptom of the disease. The gland is at first greatly enlarged, hot, and painful. The acute swelling and oedema subside after some days, and then the gland is felt to be indurated and the cord thickened. Affections of the joints varying in degree are not uncommon. The disease may last for an indefinite time. Often all the symptoms disappear for a long time and then again break out. A considerable proportion of the cases end in recovery. Semmer<sup>10</sup> has described a rather benign form of glanders which he thinks is more common in South Russia than elsewhere. The animals react to mallein in the same way as in the malignant disease, but very slight lesions are found at the autopsy.

When the disease is produced experimentally in the horse or ass by introducing the bacilli into scarified surfaces or by injecting them subcutaneously, the acute form is produced. Strauss<sup>11</sup> in 1886 showed that the intraperitoneal injection of the bacilli in the male guinea-pig was followed by characteristic lesions, and this method is one of the best and surest for confirming the diagnosis of the disease. Inoculation into the peritoneal cavity is followed, on the second or third day, by a recognizable degree of swelling of the testicles. The swollen testicles are painful, and the skin of the scrotum is red or violet and adherent to the underlying glands. The lesions reach the greatest intensity by the sixth or eighth day, and the animal dies in twelve or fifteen days. The method is not absolutely sure as a diagnostic test, and for several reasons. Nocard<sup>12</sup> has shown that an affection of horses, characterized by swelling and ulceration of the extremities, is due to a bacillus which will produce lesions in the testicle similar to those observed in glanders. In other cases the guinea-pig may die of septicæmia due to entry of the bacilli into the blood before the characteristic lesions of the testicle have had time to develop. For this reason some prefer to inoculate subcutaneously.<sup>6</sup> The inoculation had better be made with a pure culture than with the products of disease containing the bacilli, for the glanders lesions may be masked by an infection with pus organisms. In an early stage the lesions of the testicle consist in small, yellowish foci in the tunica vaginalis, or the two surfaces may be united by a thick purulent exudation containing numbers of bacilli.

In man the disease appears in both the acute and the chronic form. Taken in its entirety the clinical history of the disease, both in the acute and in the chronic form, is almost characteristic, but at a given period, and indeed for a long time, it may be impossible to make the diagnosis. This is particularly true of the chronic form. In general, the disease in man presents many points of similarity to the equine disease, but there are notable differences. The skin lesions which are so prominent in the horse appear in man only in the later stages of the disease, and abscesses in the muscles (which are very rare in the horse) are common in man and often constitute the first evidence of the disease. The disease is comparatively rare in man despite his evident susceptibility to the action of the organism and his frequent opportunities for infection. In the last ten years in Boston I have seen but two cases of infection in man despite the fact that the disease is not rare in horses. The fact that the

disease is not an extremely common one in both animals and man must be attributed solely to the slight viability of the organism and to the fact that it cannot lead a saprophytic existence.

The acute disease begins in man with chills and high fever, which sometimes takes a typhoid form. There is often intense pain in the joints and muscles, with general weakness and malaise. This condition is followed by the development, in the muscles or subcutaneous tissue, of hard swellings which rupture and discharge a thick mucoid pus mixed with streaks of blood. Even at an early period of the disease the skin over almost the entire body may be covered with pustules. In some cases there is a diffuse erysipelatous inflammation of the skin preceding the formation of pustules, or large ulcers may be formed by necrosis of the skin. The ulcers show no tendency to heal and become covered with thick, pale granulations. The nasal discharge is not so marked as in the horse, but an examination of the mucous membrane will rarely fail to show nodules, ulcers, and diffuse swelling. In two of Kütner's<sup>13</sup> cases the frontal and sphenoidal sinuses were affected, the most evident lesion being the great swelling of the mucous membrane. The muscle abscesses are usually present. Although all the muscles may be affected, the lesions are most common in the biceps, the flexors of the forearm, the rectus, and the pectoral muscles. The pustules of the skin are most common toward the termination of the disease and often appear only just before death. The pustules may be seated immediately beneath the epidermis in the corium or in the subcutaneous tissue. They may somewhat resemble smallpox pustules, but they vary greatly in size and are not umbilicated. Tedeschi<sup>14</sup> has reported a case in which there was a terminal acute meningitis. In some cases it is possible to find the atrium of infection. The disease may begin by abscess and ulceration at this point and the generalization take place by an acute lymphangitis. In many cases, and those the most severe ones, it is not possible to determine how the infection took place. This acute form of the disease is almost invariably fatal, death taking place usually between the sixth and the thirtieth day of the disease.

The chronic form may have a duration of several years. Hallipeau<sup>15</sup> has reported a case of six years' duration. The well-known case of Aufrecht, reported by Kernig,<sup>16</sup> lasted for one year and a half. In these cases there is usually an infection from a local lesion of the extremities followed by a lymphangitis extending to the lymph nodes. The local lesion may take the form of an ulcer; and abscesses may develop, followed by ulceration, the infection extending along the lymphatics. The hard cord-like affection of the lymphatics which is seen in the horse, does not take place in man. Later, abscesses appear in the subcutaneous tissue or in the muscles in various places. In some cases these muscular abscesses form the only evidence of the disease. In the case reported by Hallipeau there were numerous abscesses at intervals during the first three years of the disease, but they did not exert much influence on the general condition. These healed spontaneously in some cases, and in others after cauterization. There was then a period of latency for three years, followed by an acute attack and death. In the case reported (Kernig) the first anatomical evidence of the disease was a hard nodular swelling in the calf of the leg. This was followed after a long interval by an infiltration of the abdominal wall resulting in suppuration. Sommerbrodt<sup>17</sup> gives a case in which the symptoms were chills with fever and intense pain in the extremities. Two weeks after entry into hospital death took place from acute glanders. In the case reported by Neisser<sup>18</sup> the disease began as a small ulcer at the internal angle of the eye, and this was followed in two months by the development of an abscess in the left cheek; then later a purulent discharge from the ear and nose set in, abscesses developed in different parts of the body, and ulcers formed on the hard palate, in the nasal cavity, and in the larynx. In nearly all of the chronic cases reported the disease passes into an acute form a

short time before death. The most common lesion in fatal cases of both the acute and the chronic form, consists of pustules of the skin, particularly on the face. Chronic glanders has a very much smaller mortality than the acute, Sims Woodhead<sup>19</sup> placing it at forty per cent.

The characters of the lesions are similar in both animals and man. The glanders bacillus seems to exert about the same influence on all tissues, and the lesions vary only in the intensity of the action set up and in the different degree of reaction of the surrounding tissues. There has been a general misconception among German authors as to the character of the lesions. Virchow, who studied the macroscopic character of the lesions more than the histological details, lays particular stress upon the nodular character of the lesions, and places the disease among the granulation tumors. Baumgarten compares the nodule with the tubercle, and says that it differs from this, as regards its histogenesis, chiefly in the participation of the polynuclear leucocyte in its formation. In the glanders nodule the polynuclear leucocytes play the part that the lymphoid cells do in the tubercle, the main mass of the nodule in both being formed of epithelioid cells derived from the fixed cells of the tissue. The anatomical descriptions of the lesions given by French authors are more correct. An excellent account of the histology and the histogenesis of the lesions in man and in the guinea-pig is given by Wright.<sup>20</sup> I have been able to study the lesions in the horse by aid of a number of specimens furnished by Dr. Frothingham and by the examination of preparations secured by Drs. Wright and Magrath from human cases autopsied by them.

The most characteristic lesions in the lungs are the nodules or tubercles. These are found more frequently, and their characteristics are better marked, in the horse than in man. They may be found in any part of the lung, but are more numerous beneath the pleura than elsewhere. In their most characteristic form they vary in size from a pin's head to a pea, and are hard and circumscribed. On section they show a dry, opaque, cen-

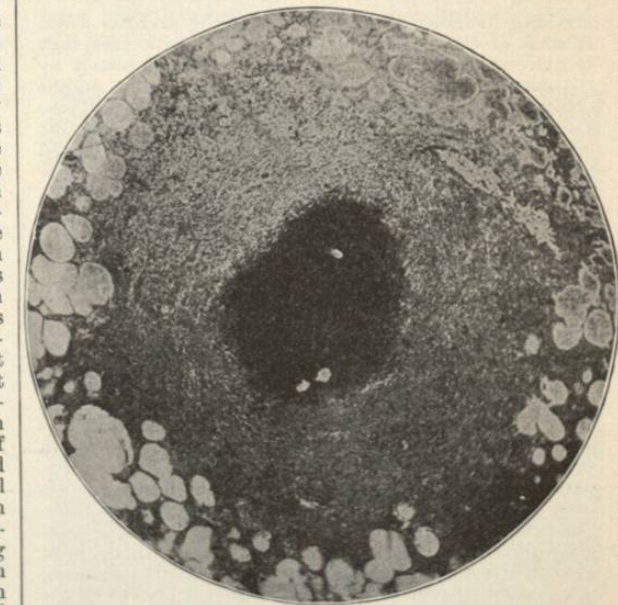


FIG. 2299.—Section of Chronic Glanders Nodule in the Lung of Horse. The dark central mass is composed of cell and nuclear debris in which no lung structure can be recognized.

tral mass, which can often be pressed out, surrounded by a pale transparent zone (Fig. 2299). On microscopic examination the centre is found to be composed of granular debris in which no tissue can be recognized. On the outside of this is a zone composed of epithelioid and giant cells with considerable lymphoid infiltration and firm

intercellular connective tissue. Immediately around the central mass of *débris* is often a mass of large phagocytic cells similar to the cells in the corpus luteum. On the outside the connective tissue extends into the surround-

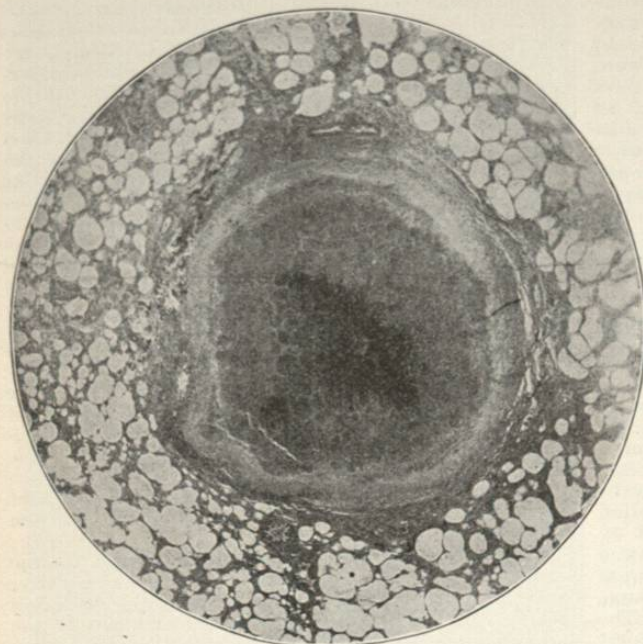


FIG. 2300.—Section of Chronic Glanders Nodule in the Lung of Horse, less advanced in its formation than Fig. 2299. In the centre of the nodule the lung structure is still visible.

ing lung structure as a thickening of the alveolar walls. In some of these nodules the central necrotic mass may be extremely small or it may be absorbed completely by the surrounding granulation tissue, the entire nodule being transformed into a small mass of connective tissue. Lime salts may also be deposited in the necrotic centre. The histogenesis of this more fully developed nodule, which very much resembles a tubercle, can be studied in those less advanced. Such a nodule is seen in Fig. 2300. In this the structure of the lung is preserved in the centre, and around this is a definite zone of connective tissue. In the dark central area the tissue is entirely necrotic, and the cells both in the exudation and in the walls are broken down and represented by nuclear detritus. In the tissue around this the necrosis is not so complete, and there is some thickening of the alveolar walls due to the formation of connective tissue. This passes in turn into the surrounding connective-tissue capsule. A more diffuse and earlier nodule is shown in Fig. 2301. In this there is a centre which is situated in close proximity to an interalveolar septum in the lung, and which is composed of a dense cellular exudation in the alveoli. All the cells in the exudation are broken down, the dark color of the centre here as in the other figures being due to the immense amount of nuclear detritus. In the surrounding alveoli there is an exudation composed of fibrin, of fragmented leucocytes, of coagulated serum, and of effused blood. In all of the younger nodules hemorrhages play an important part, and we may find areas represented by hemorrhages alone. Fig. 2302 shows a much larger area in which there are several centres filled with the closely packed nuclear detritus and around these there is an exudation similar to that in Fig. 2301. Nocard lays great stress on the presence, in the early cases, of small, rather transparent nodules in the lung close beneath the pleura. They may appear as early as on the third day after infection. They are formed by a small area of exudation surrounded by

intense hyperæmia and hemorrhage. One thing is striking in the examination of all these nodules: they are not in relation to the bronchi. In all of the figures bronchi but little altered can be seen in the vicinity of the nodules. In the material at my disposal it has not been possible to trace the formation of these masses by serial sections, but they do not appear to be due to a bronchiogenic infection of the lung by the bacilli. They occur in the lung with too great regularity and at too early a stage to suppose them due to an infection coming from the air passages higher up. In addition to such nodules it is not uncommon to find areas of diffuse pneumonia. In the horse these are often definitely lobular. In man they resemble more closely the areas of embolic pneumonia. They may be composed of cellular and hemorrhagic exudation in which there are large areas filled with nuclear detritus. The bronchi in these foci are filled with the same exudation as that in the alveoli. In some cases the surrounding interlobular tissue is greatly thickened from an infiltration with masses of lymphoid cells, and the adjoining lung tissue is involved to a greater or less extent. Such an area is represented in Fig. 2304, which shows a longitudinal section of a large bronchus filled with exudation. In the horse foci the size of an apple and manifesting evidences of purulent exudation may be found, and these may break down so as to form abscess cavities. In man the lung lesions are rarely absent, but at the same time they rarely take the distinctly nodular form which is so often seen in the horse. In the chronic cases fibrous nodules have been described, but no detailed description of their tissue has been furnished. In the acute cases the lesions, always present, take the form of larger and smaller foci of pneumonia and abscess-formation. Hyperæmia and evidences of hemorrhage

are always found in the vicinity, and there are occasionally large areas of effused blood similar to infarctions. The pneumonia areas may resemble the nodules in having a centre totally necrotic and filled with

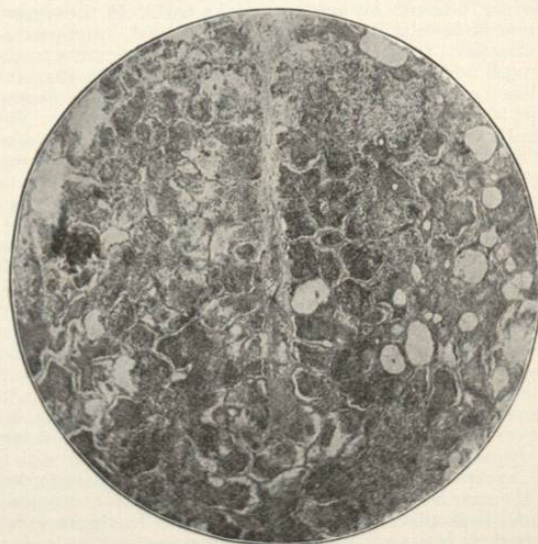


FIG. 2301.—Section of Beginning Nodule in Horse's Lung Adjoining an Interlobular Septum. The darker central portion is composed of cellular and nuclear detritus. The walls of the alveoli are necrotic.

nuclear *débris* and around this a less intense fibrinous, cellular, and hemorrhagic exudation. The liquefaction of the exudation gives rise to abscesses. In man also

the foci are more frequently found beneath the pleura. There is no reaction in these acute cases on the part of

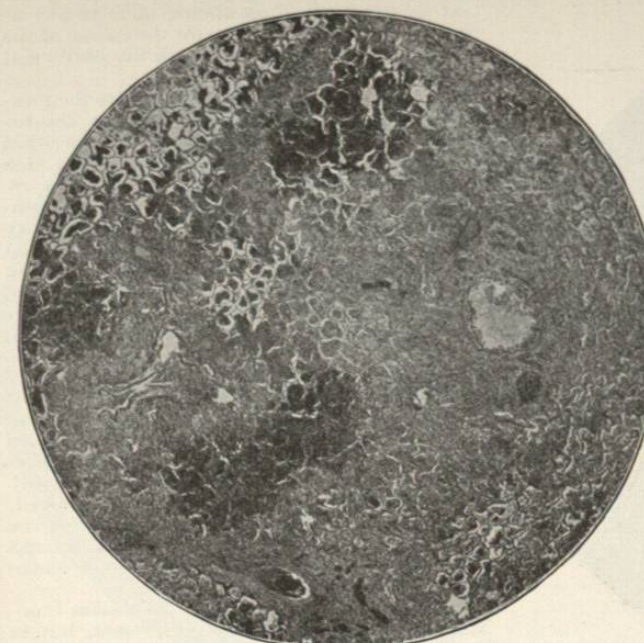


FIG. 2302.—Section of More Diffuse Acute Nodule in Lung of Horse Showing Several Centres.

the lung. It is not an uncommon thing to find abscesses without any walls, representing cavities in the tissue surrounded by hemorrhagic and partly necrotic lung tissue.

There is rarely opportunity to examine the more chronic abscesses in the muscle. In those of an acute character the contents are composed of cell and nuclear detritus with scarcely a single cell showing well-preserved nucleus and protoplasm. In a small abscess in the pectoral muscle, in one of our cases, the abscess cavity contained on the edge a small amount of detritus, and all around there were degenerated and hyaline muscular fibres. There was no reaction on the part of the tissue and little or no surrounding cellular exudation. The muscular fibres seemed literally to melt away in the process.

The skin nodules (farcy buttons) in the horse are formed by an intense leucocytic infiltration of the skin and subcutaneous tissue with numerous foci of hemorrhage. In the beginning intense congestion and edema of the surrounding tissue are present. There is also a proliferation of the fixed cells with formation of epithelioid and giant cells. The epidermis over the nodule may be infiltrated with cells and penetrated by the exudation. The hairs become loosened and drop out. The central area where the exudation is most intense becomes necrotic, the epidermis over it shares in the necrosis, and an abscess forms. The latter is likely in time to become converted into an ulcer. In other cases the necrotic mass may remain in the tissue and be gradually absorbed by a surrounding mass of granulation tissue. The formation of the skin nodule is very similar to the formation of the lung tubercle. The affection of the lymphatics giving rise to the so-called glanders cords (farcy pipes) pursues the same course as that in the nodules. There is an exudation in and around the lymphatics in the subcutaneous tissue or in the cutis. This is accompanied by intense congestion and edema of the surrounding tissue. The whole central mass undergoes necrosis and may remain for a long time as a hard cord gradually undergoing absorption, or it may soften from place to

place, or along its course, and give rise to ulcers. In some cases the necrotic tissue is discharged as a single mass. In man the skin lesions are somewhat similar to those produced by the streptococcus. In some places there seems to be very little reaction on the part of the surrounding tissues, and abscesses similar to those in the muscles are produced. Such abscesses are in the subcutaneous tissues. Sections made from the large areas of infiltration show lesions affecting both the skin and the subcutaneous tissue, but they are more marked in the skin. This shows an intense general infiltration with leucocytes and foci composed of these. The glands of the skin and hair follicles are often embedded in this and show but little change. Most of the exudation cells are broken down, and in places there is nothing but a mass of nuclear detritus. The epidermis over the area shows various changes, some of them almost peculiar to the disease. In some places the entire epidermis is cleanly separated from the tissue beneath by an exudation. In other cases and over small areas only the horny layer of epidermis remains, elevated, and covering a mass of cellular and nuclear detritus formed by leucocytes and the fragments of epithelial cells and nuclei (Fig. 2305). In still other cases there is a peculiar condition caused by a fluid exudation which has extended into the epidermis and has separated the cells. In the epidermis there may be found foci which are composed of masses of epithelial cells each separated from its connections. In the loose subcutaneous tissue there may be a considerable amount of fibrin in the exudation. The cellular infiltration may extend down deeply into the muscle, the fibres of which undergo necrosis. There are but few lymphoid cells and epithelioid cells in the surrounding tissue. In places the connective-tissue nuclei and the endothelial cells of blood-vessels and lymphatics have large vesicular nuclei with but little chromatin. The nuclei become increased in number, and no nu-

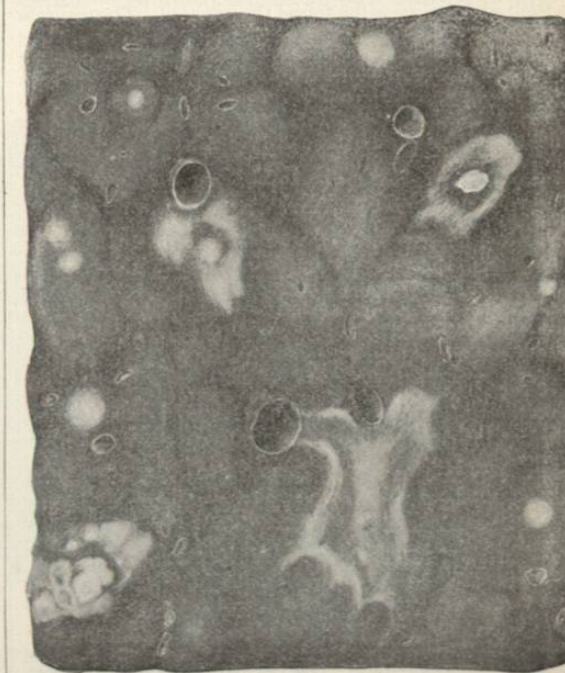

FIG. 2303.—Section of Lung of Horse (Natural Size), Showing Nodules and Cicatrices. The lobules are more prominent than is natural. (Kitt.)

clear figures are found, but occasionally there are biscuit-shaped nuclei. The process is one of degenerative direct nuclear division, and not a true proliferation.

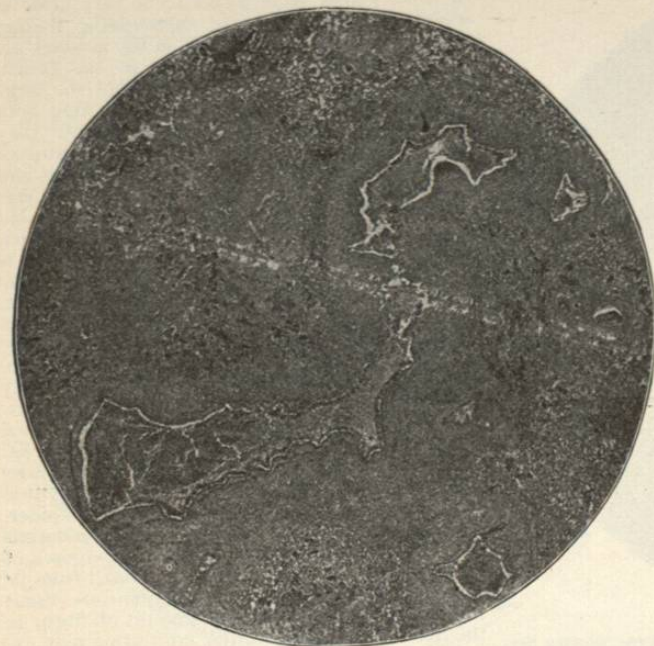


FIG. 2304.—Section of Chronic Lobular Glanders Pneumonia from Lung of Horse Showing a Large Bronchus in the Centre Filled with Exudation. In addition to exudation and hemorrhage in the alveoli there is marked connective-tissue formation.

eration of cells. The smaller vesicles and pustules show the same condition, but in these the process is confined to the dermis. The blood-vessels in the lesions and in their vicinity are often found thrombosed. The thrombi may be composed of cells, the nuclei of which show the fragmentation which is so common a feature. Nothing can be seen of the lymphatics where the process is most intense, but a study of the surrounding oedematous tissue shows that the same condition can be found here which is so common in the horse. Both the smaller and the larger lymphatics lying in a tissue which shows no lesion beyond a slight cellular exudation and the separation of the fibres due to the oedema, may be filled with masses of cells and nuclear detritus (Fig. 2307). In some cases the process extends through the wall, and a small abscess may be formed of which the lymphatic is the centre. Fig. 2306 shows such an area. The space in the centre represents the vessel from which the exudation has fallen in the preparation of the specimen.

The lesions in the mucous membranes are similar to those in the skin, with the exception that there is a great deal more extensive proliferation of the fixed cells. I have not had an opportunity to examine any of the distinct nodules formed in the mucous membrane, nor have I examined any of the chronic lesions. In the acute cases, in which swelling of the mucous membrane is the most marked characteristic, there is a dense accumulation of lymphoid and epithelioid cells in this membrane. Polynuclear leucocytes are numerous, both diffusely scattered among the other cells and in small masses chiefly on the surface. However, the individual accumulations of these leucocytes are never so large here as they are in the other tissues. Many of them, especially those scattered diffusely, have normal nuclei, but in most of them the nuclei are fragmented. The epithelium is for the most part destroyed, only fragments of it remaining. The participation of the connective-tissue cells in the process is shown in the horse by the enormous radiating cic-

trices formed in the healing (Fig. 2298). It is difficult to explain these differences in the character of the process in the mucous membrane except by the assumption that in the mucous membrane there is a comparatively free opportunity for the escape of the exudation, carrying with it both the bacilli and the toxic products.

The lesions in the testicles consist in the presence of small foci of suppuration in the tunica, rarely in the testicle itself. In the other viscera the lesions are unimportant. One case of death from acute meningitis in man is reported by Tedeschi, the infection of the meninges having taken place, most probably, by way of the blood. Abscesses have been described in the liver in several cases in man, but they are more common in animals, particularly in the guinea-pig. Several cases also of abscesses of the bone marrow have been reported, and in the Tedeschi case of meningitis there was osteomyelitis of the tibia following an abscess. I have not found any descriptions of cases of acute nephritis, and in the kidneys of the human cases examined by me the degenerative lesions were slight. Nor are there any of the focal necroses in the liver which are so frequently found in other infections. There is some swelling of the spleen in the acute cases, but the lesions are confined to hyperemia. In the lymph nodes there may be abscesses and foci of leucocytic infiltration.

The relation of the bacilli to the lesions is obvious. The bacilli are always present, but in variable numbers. In some cases they may be numerous, and in others they are found only after long search. They are difficult to find in sections, for there is no distinctive stain for them, and they are colored less deeply than the fragments of nuclei. They are found in the exudation and not in the surrounding tissue.

They are always associated with the products of the disease, and the free discharge of these products from the affected mucous surfaces gives every possibility of the extension of the infection. When the bacilli enter

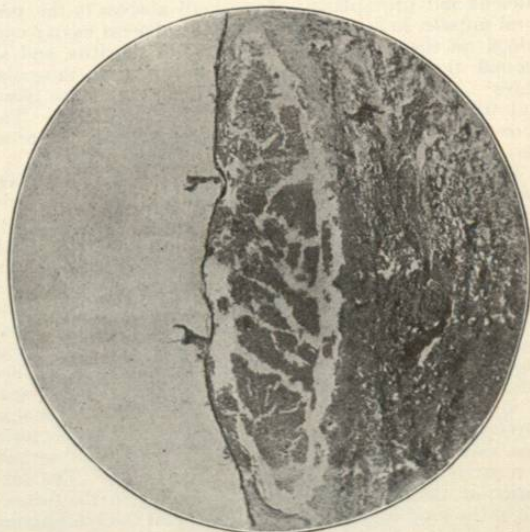


FIG. 2305.—Section of an Unruptured Pustule in the Skin of Face from an Acute Case of Glanders in Man. The horny layer is still intact. The other cells of the epidermis are necrotic and their fragments are mingled with the exudation.

the tissues they may or may not produce a lesion at the point of entrance. In Wright's case there was an intense inflammation of the thumb where the infec-

tion took place, and this was followed by gangrene. In one of Küttner's cases in which the infection took place in the foot, there was a large ulcer on the heel. In other cases there has been no local lesion at the probable

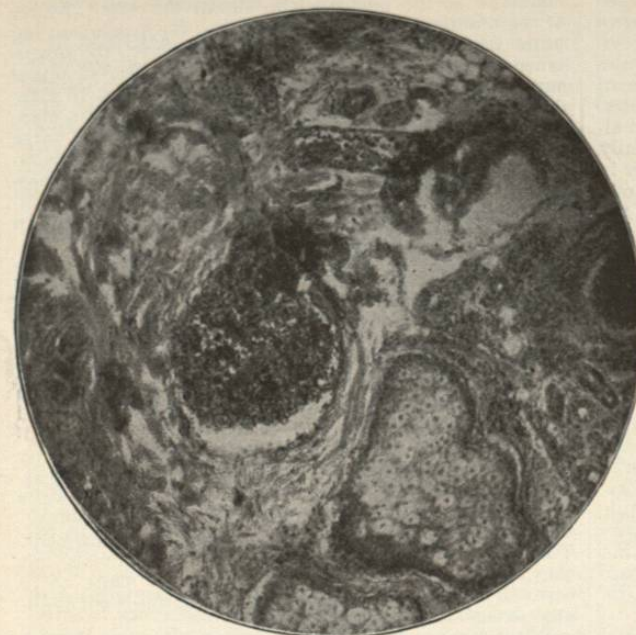

FIG. 2306.—Section of the Human Skin in the Vicinity of an Area of Infiltration and Pustule Formation Showing a Lymphatic Filled with Cellular and Nuclear Detritus. Slight cellular infiltration in the surrounding tissue.

point of infection, or else it was of an insignificant character. The bacilli rapidly enter into the lymphatic circulation and into the blood. From the blood they may be deposited in various tissues, and in many cases they remain in the blood or are again introduced into it, and so give rise to septicæmia. They have repeatedly been found in the blood in acute cases in both animals and man. They may be found in cultures, on microscopic examination, and by inoculating other animals with the blood. The situation of the lesions points to blood infection, but the bacilli, probably generally distributed, find in but few tissues suitable conditions for growth. There are great differences in this respect in different animals. Thus the testicles which are constantly affected in the guinea-pig are rarely affected in the horse, and still more rarely in man. Abscesses in the muscles, frequent in man, do not occur in the horse. There seems to be an equal tendency in all animals to affections of the lungs, skin, and mucous membranes of the nose. There is little probability that the lesions in the nose come from surface infection. They are almost constantly present even in cases in which the infection surely was from other surfaces. Wherever the lesions are produced by the bacilli they tend to extend further by means of the lymphatics. This is seen particularly in the skin and also in the diffuse lesions in the lungs. The general character of the lesions is the same in all animals. The bacilli produce a rapid and abundant exudation of polynuclear leucocytes. These form the central focus. Around these foci there will be found evidences of intense congestion, of hemorrhage, and of fibrinous and serous exudation. These changes will be found to be less marked in the mucous membrane. The bacilli

are found in greatest numbers or exclusively in the central mass of leucocytes. Destruction of the leucocytes and of the tissue containing them rapidly follows. The cells are fragmented and the nuclei converted into masses of nuclear detritus. The broken-up chromatin has a peculiar way of flowing together and forms large irregular clumps. In some cases a single well-preserved leucocyte is found in the central exudation. Lymphoid cells may be found in the surrounding tissue, but none in the centre. There is no other infectious process which produces such complete destruction and disintegration of the exudation cells. In certain cases in which the bacilli are less virulent or the tissues more resistant or in which unknown favoring conditions are present, there is a marked reaction of the surrounding tissues leading to the formation of an encircling band of granulation tissue and afterward of connective tissue. In the mucous membranes the tissue reaction is more marked than in either the lungs or the skin.

Mixed infections occur, but they are not the rule. Streptococci have been most frequently found as the accompanying organism.

The way in which the bacteria infect the surroundings is apparent from the situation of the lesions. Everything that the horse touches, everything in his vicinity may become contaminated and a conveyer of the organism. The abundant discharge from the nose, which by the snorting of the animal may be thrown a considerable distance, contains the bacilli in large numbers. The abundant discharge from the skin ulcers contains them. They are contained in the urine even when there is no lesion in the kidney, and they pass through the vessels of the placenta. The skin becomes contaminated either from the ulcers or from the nasal discharge. The harness, especially the bridle or hal-

ter, the stall, the litter, the food, the drinking-vessels all become infected. There is little doubt that many cases of infection in horses take place from the public drinking fountain. The water becomes infected from a horse with

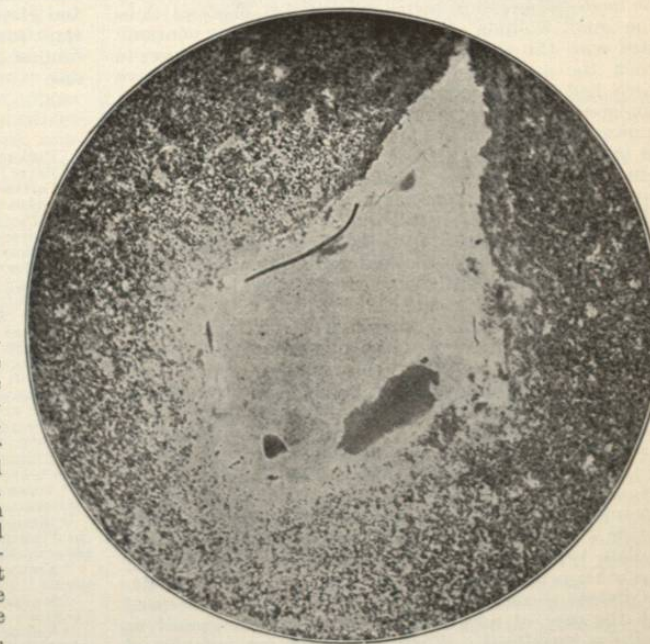


FIG. 2307.—Section through a Small Abscess in the Dermis which has Formed Around a Lymphatic. The space in the centre represents the lymphatic from which the contents have been lost.

nasal discharge, and a horse drinking shortly afterward from the same fountain will almost surely be infected. Close contact of the horses favors infection. Thus horses in a pasture where they are mouthing each other and where the food is infected are more apt to acquire the disease from one another than are horses in a well-managed stable. Not only the acute but the chronic cases are a source of infection. Chronic cases which show no evidence of the disease and which have only a few nodules in the lung are often the sources for infection. Nocard relates cases in which the disease persisted in stables, and the source was discovered only by the use of mallein. Infection in the horse takes place most usually from the intestinal canal. It may be conveyed either in the food or in the drink. Nocard gave twenty horses water to drink in which he had mixed a pure culture of the bacilli. All acquired the disease, reacted to mallein, and at autopsy showed in the lungs the small acute lesions on which he lays so much stress. Infection generally takes place from small lesions in the mouth, which are very generally present and which are due to the coarse fodder. It may also take place from lower down in the intestinal canal. Infection by the respiratory tract is rare. Babes caused guinea-pigs to breathe dust mixed with a dried culture, and succeeded in producing infection in two out of four cases. Nocard found that when virulent cultures were mixed with dust, dried, and injected into the peritoneal cavity of the guinea-pig there was no result. Cadeac injected a pure culture directly into the trachea of an ass without producing infection. Infection through the uninjured skin probably does not take place in natural conditions. Both Babes and Nocard succeeded in infecting guinea-pigs by rubbing the skin with pure cultures mixed with vaseline, but Nocard was not able to infect the ass in this way.

The disease in man is almost confined to those concerned in the care of horses, as coachmen, stablemen, etc. It is curious that more cases are not found in women, in view of the way in which they sometimes lavish caresses on a favorite horse. I have found but two cases in which infection has taken place from man to man: one the well-known case of Aufrecht (infection from autopsy), and a case reported by Zowadski<sup>21</sup> in which a physician infected himself in opening a supposed pyæmic abscess of the leg. Both physician and patient died of glanders. The mode of infection seems in a number of cases to be from small wounds of the skin which become contaminated with the virus. There have been several cases in which the infection took place from the conjunctiva which had become contaminated by the snorting of a glandered horse. In many cases the mode of infection is unknown, and even in a number of cases in which, from the situation of the first lesions noticed, the infection seems to have taken place from the skin, it is not certain that the skin lesions were not secondary.

**Diagnosis.**—A careful study of the phenomena of a case of acute glanders in man, from the beginning to the terminal pustular eruption of the skin, will generally enable us to make a diagnosis with some certainty. The diagnosis should always be made and can be made with certainty by the examination of the products of the disease. The microscopic examination of the pus from an abscess in the muscles of an extremity, showing the complete destruction of cells and nuclei, together with the presence of bacilli resembling glanders bacilli morphologically, is almost sufficient to make the diagnosis. Certainty can be reached by culture of the suspected material and by inoculation of a guinea-pig. In one of the acute cases seen here in Boston, the diagnosis was made from the microscopical and bacteriological examination of the sputum. Early in the disease when the symptoms may simulate typhoid fever, acute articular rheumatism, or some other acute infection, the diagnosis cannot be made. The disease so rarely appears except in those concerned with the care of horses that the occupation should be carefully considered. When the lesions are established and when it is possible to examine their products,—whether they are abscess contents, lung expectoration,

or nasal discharge,—the diagnosis can and should be made by bacteriological examination and animal inoculation. In those cases in which there is an abundant pustular eruption the disease may present some similarity to variola. It can be distinguished from this by the character of the pustules (the almost universal absence of the umbilication; the varying size; the accompanying bullæ with frequently hemorrhagic contents; the subcutaneous abscesses, the loss of epidermis without actual suppuration; and the grouping of the pustules, in glanders). Very little is known of the use of mallein in man. Bonome<sup>22</sup> reports a chronic case (in a man and of three years' duration) in which mallein was given as a therapeutic agent and in which recovery took place. It produced a violent reaction. It has not been used sufficiently to determine its value as a diagnostic agent in the case of human beings.

In horses there is little difficulty in making the diagnosis when the disease is established, and in cases of doubt the careful administration of mallein will settle the diagnosis.

**Treatment.**—The treatment of glanders in man should be directed to the relief of the conditions. Abscesses and ulcers should be treated surgically. There is no reason to believe that the course of the disease can be influenced by the internal administration of drugs. Mercurial preparations have been used and they are recommended by Koranyi. All medication has been used with the greatest effect in chronic cases, and in estimating the results of treatment it must be remembered that a large percentage of these cases recover independently of treatment. There should be no attempt at treatment of animals, but they should be killed when the diagnosis is made, or, in case the necessary knowledge for making this is not available, when the disease is suspected.

With our present knowledge of the bacteriology and pathology of the disease, the sources and modes of infection, there should be no excuse for the existence of the disease. No disease could be more easily stamped out. The Equidæ are the sole source of infection. The disease is easily recognized by the mallein test, which should be made in all suspected cases. If there is a suspicious case in a stable, and this case gives a positive reaction, all the animals in the stable should be tested. It may happen that a chronic case with slight lesions located in the lungs, and giving rise to no suspicious symptoms, can be a constant source for spreading infection. Public drinking-fountains undoubtedly assist in the extension of the disease.

W. T. Councilman.

BIBLIOGRAPHICAL REFERENCES.

- <sup>1</sup> Hecker: Geschichte der Heilkunde, Berlin, 1829.
- <sup>2</sup> Rayer: De la Morve et la Farine chez l'homme, Paris, 1837.
- <sup>3</sup> Lafosse: Abhandlung von dem Sitze des Rotzes bei den Pferden, Frankfurt und Leipzig, 1754.
- <sup>4</sup> Löffler und Schultze: Ueber den Bacillus des Rotzes. Deut. med. Wochenschrift, 1882.
- <sup>5</sup> Koranyi: Nothnagel's Specielle Pathologie und Therapie, 5 Band.
- <sup>6</sup> Mallory and Wright: Pathological Technique, Philadelphia, 1901.
- <sup>7</sup> Nocard: Ueber das Mallein. Berl. thierärztl. Wochenschrift, 1894.
- <sup>8</sup> McFadyean: The Diagnostic Value of the Local Reaction after Mallein. Journal of Comp. Path. and Ther., vol. viii.
- <sup>9</sup> Nocard et Leclainche: Les maladies microbiennes des animaux, Paris, 1896.
- <sup>10</sup> Semmer: Ueber die gutartige heilbare Form d. Rotzes. Deutsche Zeitschrift f. Thier-Medicin, Bd. xx., 1894.
- <sup>11</sup> Strauss: Sur un moyen de diagnostic rapide de la Morve. Arch. de Méd. expérimentale, 1886.
- <sup>12</sup> Nocard: Sur la valeur diagnostique de la malleine. Bull. de la Soc. Cent. de Méd. Vet., 1893.
- <sup>13</sup> Küttner: Beiträge zur Frage ueber d. Rotz beim Menschen. Virchow's Archiv, vol. xxxix., p. 548.
- <sup>14</sup> Tedeschi: Beitrag zum Studium d. Rotz-Meningitis. Ref. in Baumgarten's Y.-B., 1892, p. 258.
- <sup>15</sup> Hallipeau et Jeanselme: Etude clinique et expérimentale sur un cas d'infection forcino-morveuse chronique. Annales de Dermatologie et de Syphilis, 1891, p. 273.
- <sup>16</sup> Kernig: Ein Fall von chronischem Rotz beim Menschen. Zeitschrift f. klin. Med., 1887, Bd. xli., p. 191.
- <sup>17</sup> Sommerbrodt: Ein Fall von Rotz-Krankheit beim Menschen. Virchow's Archiv, 1864, Bd. xxxi., p. 463.
- <sup>18</sup> Neisser: Ein Fall von chronischem Rotz. Berl. klin. Wochenschrift, 1892, No. 14.
- <sup>19</sup> Sims Woodhead: Article Glanders, Allbutt's System, vol. ii., p. 513.
- <sup>20</sup> Wright: The Histological Lesions of Acute Glanders in Man and

of Experimental Glanders in the Guinea-Pig. Journal of Experimental Medicine, vol. i., p. 576.

<sup>21</sup> Duval, Gasne, and Guillemot: Observations de morve aigue humaine. Arch. de Méd. expér. (1896), vol. viii., p. 361.

<sup>22</sup> Bonome: Neue Beobachtungen ueber d. diagnostische und therapeutische Wirkung d. Stoffwechselprodukte d. Rotzbaecillus, etc. Deutsche med. Wochenschrift, 1894, p. 733.

**GLAUCOMA.**—The name of this affection of the eye has been bestowed upon it on account of a greenish appearance (*γλαυκος*) of the pupil, which, although present only in rare cases, may be observed as one of its symptoms. This name is a misnomer. It is, however, generally adhered to. More recent names, which were adapted to special theories regarding the character of the affection—as, for instance, ophthalmia arthritica, choroiditis serosa, etc.—have never been universally adopted.

**PATHOLOGY.**—The chief characteristics of glaucoma are a slowly or rapidly progressing diminution of the acuity of vision, combined with an occasional or continued increase of the intra-ocular pressure, and an excavation of the optic-nerve papilla. Around these chief symptoms and conditions we find grouped a number of other symptoms which characterize the different varieties of the disease. These varieties are known as *glaucoma simplex acutum*, *glaucoma simplex chronicum*, *glaucoma inflammatorium acutum*, *glaucoma inflammatorium chronicum*. When any one of these forms of glaucoma occurs in an eye which has not previously been affected in a manner such as to cause the development of glaucoma, we speak of the glaucoma as being *primary*; when, on the other hand, a previously diseased eye is, in consequence of this former disease, attacked by glaucoma, we call it a *secondary* glaucoma. We can furthermore, as a rule, recognize three stages in the development of all forms of glaucoma, the first of which is called the *prodromal* stage, the second that of *glaucoma evolutum*, and the last that of *glaucoma absolutum*.

What are usually described as the *prodromes* of glaucoma are observed in a large majority of the cases, and are in reality a series of slight attacks of acute glaucoma. This prodromal stage may last for many months, or even for years, until the attacks and their consequences become more serious. The prodromal attacks are not equal either in duration or in degree; yet they are not serious enough, as a rule, to cause cupping of the optic disc, nor to reduce the visual acuity lastingly. On the other hand, their early recognition is of grave importance to the patient, as the disease in these early stages is more tractable than later on. The symptoms which characterize this prodromal stage are the following: There is an appearance of a mist before the eye or eyes, and this mistiness may change in density. Rainbow colors are seen, especially in the shape of a ring around a candle flame. These rainbow-color rings do not touch the flame, but are separated from it by a dark space. The range of accommodation is reduced, and the eye appears prematurely presbyopic. This symptom is probably due to the hyperemia of the ciliary body. In some cases the eye becomes myopic, which fact can be explained only by the assumption that the crystalline lens *in toto* is pressed forward toward the cornea, and that, in spite of the fact that in this manner the zonule of Zinn is stretched,

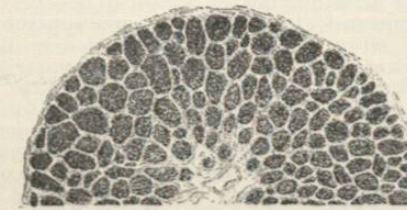


FIG. 2308.

and that an appplanation of the lens is taking place. There is pain, which may be slight or even excruciating, and which is located in and around the eye, and in the forehead, the eyebrows, the cheek bones, the nose, and

the temple. There is an increase of the intra-ocular pressure, which will manifest itself by an increase in the degree of tension of the eyeball; this increased tension

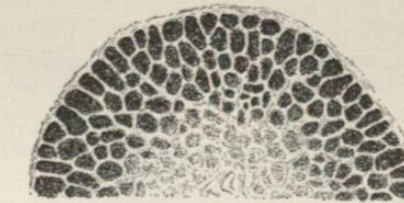


FIG. 2309.

varying from a barely perceptible to a stony hardness. The intra-ocular pressure is tested by directing the patient to look downward, then gently laying the tips of the forefingers upon the upper lid, and alternately pressing them upon the eyeball, as we do when we are searching for fluctuation elsewhere. By comparing the amount of impression we are able to make on a diseased eyeball with that which we can produce on its healthy fellow, or on the healthy eye of a third person, we can form an estimate of the increase of intra-ocular tension in the given case. According to the degree of hardness, we speak of it as +T. (tension) +T<sub>1</sub>, +T<sub>2</sub>, and +T<sub>3</sub>. Several instruments (tonometers) have been invented to give an exact measurement, but they do not seem to be altogether reliable.

The prodromal stage passes over into that of the *glaucoma evolutum* as soon as the visual acuity is lastingly reduced.

The *Glaucoma simplex acutum* is, if ever, very rarely observed. It would seem to have existed in a few cases

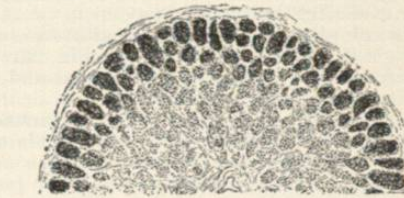


FIG. 2310.

in which sight was lost within a few hours without any inflammatory symptoms, and with barely increased pressure.

*Glaucoma simplex chronicum* is characterized by the fact that externally the eye shows no marked signs of disease. The cornea, anterior chamber, iris, and pupil appear normal. The main symptoms are: the loss of vision, the excavation of the optic papilla, and the increase of the intra-ocular pressure. The latter symptom may, however, be imperceptible, or it may be present only at times.

An increase of the intra-ocular pressure is generally accepted to be the cause of the glaucomatous excavation of the optic papilla. The normal optic papilla has a central depression (physiological excavation) which may, in rare cases, reach so far toward the periphery of the optic papilla that at first sight it will strike the observer as a glaucomatous excavation. I have seen several cases in which the absence of all other symptoms alone convinced me of the fact that I was not dealing with a chronic glaucoma. Such a physiological excavation may have a sloping or a sharp edge, and may appear quite deep, yet it can never reach farther back than the anterior surface of the normal lamina cribrosa. In our judgment of the width as well as of the depth of such a physiological excavation we must take into consideration the fact that the optic nerve fibres, after they have passed through the lamina cribrosa, lose their marrow, become non-medullated, and are then diaphanous. Thus, a physiological excavation of the optic papilla is likely to