

bimanual examination will have given the physician a fairly accurate idea as to the shape of the uterus, and he should shape his probe or sound accordingly. The instrument is to be held lightly between the thumb and forefinger and the cervix steadied by the tenaculum. The tip is then passed into the external os and allowed to find its way along the canal. It will frequently become obstructed at the internal os by a shoulder or pocket in the mucous membrane, in which case a gentle twisting



FIG. 2434.—Skene's Curette.

motion or withdrawal will enable the sound to pass the obstacle. The probe will pass a constriction at the internal os, while the sound may be arrested. Sometimes, in anteflexion, the constriction may be spasmodic in character: if such is the case, the stricture will relax if the sound is held firmly against it for a few moments. When the instrument reaches the fundus, the forefinger is slid along the shaft until it comes in contact with the cervix. The probe or sound is then withdrawn and the depth of the uterine canal can readily be noted.

The sound should not be used to determine the mobility of the uterus. It is such a powerful lever that the uterine mucosa will be unnecessarily injured even if worse damage is not done. The degree of mobility of the uterus can be determined better and more safely by the bimanual examination. In the healthy uterus the sound, if skilfully passed, should not cause either pain or hemorrhage. The occurrence of one or both of these symptoms denotes a diseased condition of the endometrium. The patency of the external and internal os, irregularities on the uterine mucosa, and the presence of growths in the canal are ascertained by means of the sound. The sense of touch, as communicated through the sound, is here brought into play, and this necessitates that the instrument must be held very lightly between the thumb and fingers in order to appreciate any delicate variation.

The use of the sound as a repositr is to be condemned. Any evidence of acute inflammation of the uterus or its appendages prohibits any intra-uterine manipulations.

**The Curette.**—The curette is a valuable instrument for diagnostic purposes. The curette for this purpose should be small, so as to pass the internal os without difficulty. It should be dull and very flexible, so that no damage can be done with it. The spoon-shaped curette, as shown in Fig. 2434, is especially adapted for diagnosis, although a dull wire curette may be used. The spoon curette enables one to scrape off shreds of tissue and epithelium from the endometrium, which should be examined under water to disclose their gross appearance, while they are to be submitted to microscopic examination for more accurate diagnosis. All that has been said in regard to employing the sound applies equally to the curette. The instrument must be properly sterilized, and given the shape of the canal which has been accurately ascertained by means of the sound or probe. It is to be used with all gentleness. The curette is not to be used in the office to curette the uterus as for an operation; it should serve simply as a means of procuring a small amount of tissue or debris from the uterine canal for diagnosis only.

**Dilatation of the Cervix.**—This is a procedure which is sometimes necessary in order to admit the passage of the examiner's finger into the uterine canal for purposes of diagnosis. As it is of such a nature as to require an anesthetic for its proper performance, as well as the usual preparations for a surgical operation, its description does not belong in this article.

**Examination of the Urethra and Bladder.**—This subject is fully treated in Volume II. of this work.

**The Aspirating Syringe.**—The ordinary aspirating syringe used in exploring the chest for pleuritic effusions is all that is necessary. It is desirable to have a long curved needle, as the curve greatly facilitates its intro-

duction through the vaginal vault. Cystic or inflammatory masses which are situated low down in the pelvis, and which can be palpated by the examining finger through the vaginal vault, can be safely punctured with the needle and the contents withdrawn by the syringe for examination.

**The Microscope.**—The aid of the microscope for differential diagnosis is of especial value in gynecological examinations. The recognition of the gonococcus by the

microscope is of prime importance in investigating the character of vaginal or other discharges. In fact it is impossible to be sure of the character of a discharge without its aid. As the important position that the gonococcus holds as an etiological factor in diseases of women becomes better known, the necessity for the use of the microscope by the gynecologist appears in a clearer light. Commencing epithelioma and carcinoma are to be detected with positiveness only by submitting uterine scrapings or small pieces of cervical tissue to microscopical examination. It must also be resorted to, in many cases, in differentiating malignant from non-malignant growths.

George Gray Ward, Jr.

**HÆMATEMESIS.** See *Stomach, Diseases of.*

**HÆMATIDROSIS** is a functional disturbance of the sweat apparatus whereby blood, through diapedesis into the coils and ducts from their surrounding vascular plexus, becomes mingled with the sweat and appears with it upon the normal skin, producing the phenomenon of so-called "bloody sweat." It is an exceedingly rare occurrence, and when observed the subject has been generally a highly neurotic person undergoing some strong emotional disturbance. In some instances it has seemed to be a form of vicarious menstruation. It has been observed in the newborn. The points where it has been observed to occur are the face, ears, umbilicus, feet and hands in limited areas, giving rise to the term "bleeding stigmata" and other names. Treatment is that of the patient.

Charles Townshend Dudge.

**HÆMATOCELE, RETRO-UTERINE OR PELVIC.** See *Extra-Uterine Pregnancy.*

**HÆMOGALLOL, HÆMOL.**—Two patented compounds prepared from the coloring matter in the blood and thought to be more readily absorbed than other preparations of iron. The first is obtained by the action of pyrogallol, the latter by the action of zinc dust.

Hæmogallol is a brownish-red powder, very soluble in water. The dose is from gr. v. to x. three times a day. Hæmol is a black powder, also very soluble and administered in the same dose. They have been recommended for the treatment of chlorosis and anæmia.

Beaumont Small.

**HÆMOLYMPH GLANDS. (HISTOLOGY AND PATHOLOGY.)**—The hæmolymp glands are lymphadenoid structures occupying a position intermediate between the spleen and ordinary lymphatic glands. In structure they closely resemble the latter, the essential difference between the two being that they possess blood sinuses in place of lymph sinuses. Transition forms between the two, however, exist; a gland may contain both lymph and blood sinuses; but the presence of the latter, however small, is sufficient warrant for its classification as a hæmolymp gland. There are also transition forms between the hæmolymp glands and spleen, many of the former, particularly in the lower animals, possessing a spleen-like pulp. The spleen itself may be regarded as a hæmolymp gland; and undoubtedly many of the so-called accessory spleens fall into the class of hæmolymp glands.

**OCCURRENCE.**—The existence of hæmolymp glands was first noticed in the lower animals, particularly those used for food purposes. In the steer, pig, and sheep these structures are very numerous in the prevertebral fat, and conspicuous because of their deep blood color. From their number and size in these animals it is reasonable to suppose that their function is of importance. Butchers and meat dealers have long been acquainted with their gross appearances, but have usually regarded them as blood clots. From the scientific side they have been strangely neglected, though as early as 1857 Leydig pointed out the close resemblance between these glands and the spleen. More recently they have become objects of scientific investigation, and have been found to be present also in the goat, horse, dog, rat, guinea-pig, common fowl, and turkey.

Their presence in man has only lately become a matter of careful study, though lymph glands with blood-containing sinuses have been many times observed. Such findings were, however, interpreted as ordinary lymph glands into whose lymph sinuses there had been a hemorrhage or backward flow of blood. H. Gibbes, in 1884, was the first observer to consider such glands to be permanent and independent structures. A similar view was taken by Robertson in 1890, and to this observer we owe the designation hæmolymp gland, this name having been suggested to him by Dr. Russell. The constant presence of these glands in the human body

First. Lymph glands containing blood sinuses are constantly present in the human body in all conditions and at all ages.

Second. The structure of such glands differs in many respects from that of ordinary lymphatic glands; and the appearance presented by hemorrhagic lymphatic glands is wholly unlike that of a hæmolymp gland.

Third. These glands in the human body show many points of similarity to the hæmolymp glands found in the steer and sheep, and the latter from their number, size, constant occurrence, and individual structure must be regarded as organs *sui generis* without question.

**LOCATION.**—In the lower animals the hæmolymp glands are found chiefly in the prevertebral fat, along the course of the aorta, renal and adrenal vessels, brim of the pelvis, and in the root of the mesentery. They rarely extend far out into the latter, but are occasionally found in the omentum and epiploica. They are also of rare occurrence in the mediastinal region. In man they are found in greatest numbers in the prevertebral, retroperitoneal, and cervical regions, in the neighborhood of the adrenal vessels, along the brim of the pelvis, in the root of the mesentery, but rarely extending far out into it, and are of very rare occurrence in the epiploica and omentum. They are also rare in the mediastinal tissues and along the thoracic aorta, except under conditions in which there is a general enlargement of all the hæmolymp glands of the body, as in certain forms of anæmia and

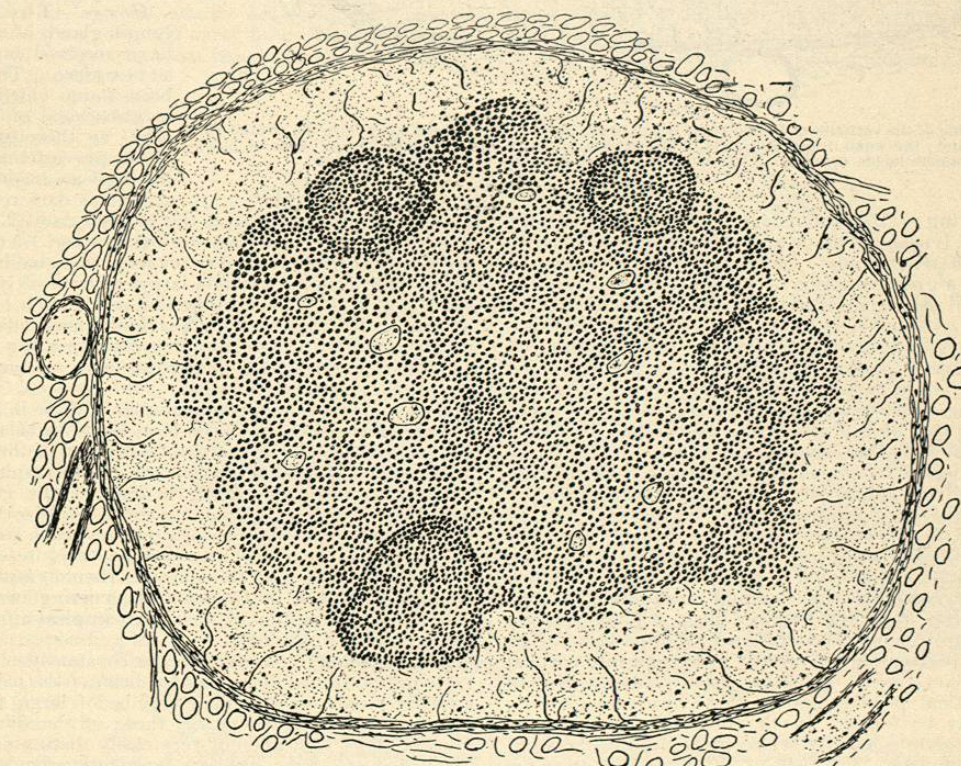


FIG. 2435.—Common Type of Hæmolymp Gland from Steer. Peripheral blood-sinus. Camera lucida drawing. Leitz objective 3; eyepiece No. II. Reduced one-third.

was confirmed later by Gibbes and Vincent, and more recently by the present writer. According to the investigations of the latter, lymph glands containing blood sinuses are found constantly in the human body, at all ages, and in both normal and pathological individuals. That these glands are organs *sui generis* and not hemorrhagic lymphatic glands is evident from the following facts:

leukæmia. This fact suggests the possibility of new formation of these structures in these diseases or their existence as resting glands too small to be found under normal conditions.

**HISTOLOGY.**—*Bullock.*—Hæmolymp glands are found in the prevertebral fat of this animal to the number of several hundred. Their deep red color contrasted with the white fat in which they lie embedded makes them