passages are commonly associated with injuries of the liver, the operations for the treatment of which are given above. There are often coexistent wounds of the intestine, pancreas, kidney, etc.

If an injury of the gall-bladder or bile-ducts is not recognized until the symptoms of collapse have passed off, and jaundice or fluid in the peritoneal cavity suggests it, recovery may follow repeated aspiration of the extravasated bile. The tear in the gall-bladder may heal spontaneously. However, if the strength of the patient permits it, it is better to make a short incision which will permit escape of the fluid and will at the same time enable the surgeon to inspect the biliary tract.

CHAPTER XXIV.

DISEASES OF THE LIVER.

ABSCESS OF THE LIVER.

ACUTE hepatitis, a disease more often seen in the tropics than in the temperate zone, frequently leads to abscess of the liver. It is thought to be due to micro-organisms which enter the liver from the intestine through the lymphatic or blood- or biliary vessels. The excessive use of alcohol, strong cathartics, etc., are considered predisposing factors in this disease. Be that as it may, white men are the chief sufferers from this affection, and these people, especially when only a short time in the tropics, are unwilling to content themselves with the simple and scanty fare of the natives. The tropical abscess of the liver follows dysentery in the majority of cases. Several observers have found the amœba of dysentery in the pus from the abscess. There are also instances in which hepatic abscess has followed malaria, influenza, and yellow fever.

This subject is of practical importance to physicians living in a temperate zone, since those who return home after a long stay in the tropics occasionally develop hepatic abscess. Sometimes a foreign body has been found in an abscess of the liver—fishbone, a bit of straw, etc. Abscess may also be due to contusion, the infection in such cases being introduced through the blood or biliary channels. In open wounds of the liver the infection may enter from without. Round worms may enter the biliary passages and set up abscess. Other agents are coccidia, the ray fungus of actinomycosis, and, in rare instances, the bacilli of tuberculosis. A syphilitic gumma of the liver may suppurate. Abscesses secondary to lesions of echinococcus and cholelithiasis are somewhat more common.

Any infectious disease, and especially typhoid fever, may set up suppurative cholelithiasis and cholangitis, which in turn may produce pericholecystitis, pericholangitis, suppurative thrombosis of the veins, and abscess of the liver. Ulcer of the stomach or duodenum may produce adhesions to the liver and break through its capsule, forming an abscess in the substance of the liver. Abscess of the kidney may act in a similar way.

The metastatic abscesses of pyæmia, some of which may occur in the liver, have little interest for the surgeon, as they are lesions of the last stage of this disease. Abscess of the liver which follows ulceration in some organ connected with the portal system is of greater sig-

nificance. As examples may be mentioned appendicitis, periproctitis, carcinomatous ulcer of the intestine, or, more rarely, of the stomach or of the pancreas. Such a process sets up suppurative thrombosis of the veins, which in turn produces septic emboli and abscesses in the liver. Gangrene of the lung, putrid bronchitis, and ulcerative endocarditis may be the source of septic emboli which reach the liver through the hepatic artery. Peripheral suppuration may produce emboli which pass the capillaries of the lungs and set up abscess in the liver. This fact has been variously explained. It is probable that parenchymatous swelling of the liver narrows its capillaries so that emboli which pass the capillaries of the lung are caught in the liver. It has sometimes been asserted that owing to the weak heart and limited abdominal resorption there is a back flow of blood from the vena cava into the hepatic vein, giving rise to septic embolism.

Pathological Anatomy.—Abscesses of the liver may occur singly or in groups. Zancarol found multiple abscesses in 38 per cent. of 211 cases; Jimenez, in only 6 per cent. of 297 cases. The pus frequently contains amœbæ. Giordano found it sterile in 58 per cent. of the cases, a proof that the micro-organisms in the course of time either die out or become scattered. Germs frequently found are staphylococcus aureus and albus, bacterium coli, and Fränkel's pneumococcus. The majority of abscesses of the liver develop in the right lobe and near the convex rather than the concave surface. Such an abscess may be of varying size. In rare cases it occupies almost the whole liver. As it develops it may break into the various neighboring organs or spaces. Tropical hepatic abscess is for the most part solitary, while metastatic abscesses of a pyæmic nature and those due to cholangitis are usually multiple.

Course of the Disease.—The development of a hepatic abscess varies according to the nature and origin of the infection. Tropical abscess grows slowly without marked symptoms. It may suddenly perforate into the colon, the stomach, lungs, or other viscera, with considerable relief to the patient, or into the vena cava, pericardium, or peritoneal cavity, producing sudden death. If abscess of the liver is secondary to dysentery, malaria, or echinococcus, its symptoms may be obscured by those of the primary disease for a long time. Spontaneous recovery is extremely rare, yet it may occur, the abscess becoming surrounded by a thick fibrous capsule and its contents being finally resorbed. Such a happy outcome is so rare that the prognosis of cases left to themselves is uniformly unfavorable, nor can one trust to rupture of an abscess into some hollow organ with spontaneous recovery. The prognosis even when operative treatment is employed varies according to the source of the disease, the presence of multiple abscess, the general condition of the patient, and other factors. Those writers who have reported a series of cases have usually placed the mortality of operation at 50 per cent. or even higher. The disease may be expected to last from three weeks to six months, or even longer if the walls of the abscess are very firm.

Symptoms.—Abscess of the liver may run its course without symptoms. Rouis says that the disease is latent in a third of the cases. The symptoms are often obscured by those of the primary disease of which the hepatic abscess is merely a complication. The characteristic group of symptoms, namely, fever, local pain, increased hepatic dulness, and tumor, were found in only 8 per cent. of Rouis's cases. Some authors cite as characteristic of the disease a tired, sad expression, a peculiar yellowish tint of the skin and eyes, not exactly like jaundice, and the position which the patient takes to relieve his pain by relaxing the right rectus muscle. The favorite position of the patient is upon his back with the right thigh somewhat flexed and the body bent toward the right side.

Pain may be wholly wanting in from 15 to 28 per cent. of the cases. If present, it may be constant, or may shoot to the right shoulder. If the abscess is near the surface of the liver, peritoneal friction-rub may be felt and heard. In chronic cases fever may be wanting. In acute cases the fever often takes on an intermittent type so that the disease may easily be mistaken for malaria or tuberculosis. Jaundice is not well marked unless the abscess compresses one of the larger bile-ducts. The liver is altered in shape according to the situation of the abscess. Sometimes the right lobe is very prominent in the right hypochondriac region. Abscess in the convex portion of the liver presses the diaphragm upward, while abscess in the concave portion reveals itself in the epigastrium. A very large abscess may so press upon the portal vein as to cause ascites or even to dilate the superficial veins of the abdominal wall (caput Medusæ). Circumscribed œdema of the back and infiltration are signs of threatened rupture through the abdominal wall. The digestion is usually disturbed. Abscess of the convexity of the liver often sets up serous or purulent exudation in the right pleural cavity. Rupture of an abscess of the liver produces different symptoms according to its situation so that it is scarcely worth while to describe them in detail.

Diagnosis.—If a single abscess develops in the centre of the liver, or if there are multiple small abscesses, the diagnosis is often difficult. A single abscess near the surface of the liver is more easily recognized. If amœbæ or coccidia are found in the stools of a patient who complains of pain in the hepatic region, the existence of an abscess is probable. If the other symptoms mentioned are present, and especially if there is fluctuation, the diagnosis is practically certain. The fluctuation of echinococcus is tense, that of abscess less so. Aspiration may be performed for the sake of diagnosis, but it carries with it a slight risk of hemorrhage and of infection of the peritoneal cavity. A short exploratory incision made under local anæsthesia is preferable. If pus is found, operation should be at once determined upon. Percussion is a help in diagnosis if the abscess is situated in the convex portion of the liver. Symptoms of indigestion, such as pain, vomiting, and diarrhœa, have little value in making the diagnosis of

liver abscess. If the lung is compressed, or the pleura is involved in the inflammation, there may be dyspnœa and cough. In making a differential diagnosis the following conditions must be considered: 1. Echinococcus and serous cysts of the liver, in which the tension is usually greater than in abscess. 2. Uronephrosis and pyonephrosis, to be recognized by the history, by the cystoscope, distention of the colon, etc. 3. Affections of the gall-bladder, such as empyema or hydrops; the history of the disease will often serve to distinguish these conditions, which can scarcely be mistaken for abscess if the gall-bladder is still movable. 4. Cysts of the pancreas, for the symptoms of which see page 733.

Treatment.—While beginning suppurative hepatitis is to be treated medicinally, an abscess of the liver when once it has formed is amenable only to surgical treatment. If the liver has become adherent to the parietal peritoneum, the treatment is relatively simple. If no such adhesions have formed, it is the duty of the surgeon to protect the peritoneal cavity from infection. The object of treatment is thorough drainage of the abscess. Drainage through a large trocar is not sufficient. It is true that the patient is saved the necessity of a general anæsthesia and an open operation, but the trocar does not always prevent the escape of pus into the peritoneal cavity. The tube may become blocked by bits of necrotic tissue or it may slip out of the abscess cavity. Jimenez, who treated 297 patients by puncture, lost 82 per cent. of them. If a general anæsthesia is feared, local anæsthesia will suffice for incision through the abdominal wall. If the liver is found adherent, the abscess cavity is readily opened with a sharp knife and can be explored with the finger, and any foreign body in it can be removed. A large tube should then be fixed in the abscess cavity, through which irrigation with normal salt solution is to be carried out and the wound dressed with sterile gauze. If there are no adhesions between the liver and parietal peritoneum and the condition of the patient permits of delay, the surgeon may fix the liver in the wound by means of a few sutures, or by the simple introduction of sterile gauze he may stimulate the formation of adhesions. In ten days, or much sooner if necessary, the abscess may be opened without infecting the peritoneal cavity, by means of a sharp knife or a Paquelin cautery. If the condition of the patient does not permit of delay, or if the abscess is so situated that it is possible to open it without passing through the peritoneal cavity, the operation may be completed at once. The site of incision in the liver should be surrounded by gauze and the greater portion of the pus aspirated through a large needle. The liver should then be fixed to the parietal peritoneum with a number of strong catgut or silk stitches. The cavity should then be opened and drained with a glass or rubber tube. To curette such a cavity promotes a profuse bleeding and in no wise hastens the healing. The dry aseptic dressing should be changed as often as it becomes saturated, or if fever reappears. Abscesses of the convex surface often require resection of the lower ribs, or they may be opened by the so-called transpleural

method. These operations are described in the following pages. When an abscess perforates into the pleural or peritoneal cavity, an immediate operation is indicated.

The abscess cavity when drained gradually fills with granulations, a process which takes six weeks, more or less, but the healing is by no means so slow as that after an operation for echinococcus. Irrigation is not usually of benefit. The drainage-tube should not be removed until active suppuration has ceased.

After incision tuberculous abscess of the liver may be treated by injections of iodoform emulsion. Large doses of potassium iodide should be given a patient after operation for hepatic actinomycosis.

TUMORS OF THE LIVER.

Tumors of the liver may be either cystic or solid. The latter are again divided into benign or malignant. Syphilis of the liver is also considered in this section because of its tendency to tumor formation.

Cystic Tumors of the Liver.

Cysts of the liver may be either parasitic or non-parasitic. In rare cases cysts have been found due to distoma hepaticum, lanceolatum, etc., psorosperms; but practically the only parasitic cyst of human interest is that due to echinococcus.

Echinococcus of the Liver.—An echinococcus cyst is the early development of tænia echinococcus, a tapeworm of three or four joints, measuring about 5 mm. (0.2 inch). This is found in the upper portion of the duodenum of dogs. If ripe seeds of this parasite find their way into the human stomach or intestine, they pass through the portal vein or the thoracic duct and lodge in the liver, lungs, kidneys, spleen, etc., and there develop. The ripe eggs may find their way into the human stomach through drinking-water, uncooked vegetables, etc., or the dog which is affected with them may lick a plate or the face of a man, etc. The domestic cat and the rabbit may also be the source of an echinococcus infection. Echinococcus is common in Iceland and in other cold countries in which men and dogs are closely housed together. When the embryo is deposited in the liver it develops very slowly, so that in five months it forms a cyst measuring only 2 cm. (0.8 inch) in diameter. It is surrounded by a connective-tissue capsule. Within this there is a true capsule of the cyst called the cuticle, yellowish or whitish, firm, and lined with a tender parenchyma, from whose cells the heads of the tapeworms, or scolices, develop. These are at first conical bodies united to the capsule by a slender pedicle. They are provided with suckers, surrounded by two rows of hooks. When fully developed, the scolices are separated from the parent membrane and float free in the cavity of the cyst. For a detailed description of the development of endogenous, exogenous, and multilocular forms of echinococcus the reader is referred to works on pathology.

The normal echinococcus fluid is colorless, clear, or slightly opalescent, and either neutral or slightly acid or slightly alkaline. Its specific gravity varies between 1.000 and 1.015. It contains no albumin and is not clouded by boiling or by contact with nitric acid. It contains sodium chloride, succinic acid, ptomaïns and toxins, which after repeated puncture of the cysts may leak into the peritoneal cavity and set up symptoms of general intoxication. A definite diagnosis of echinococcus can only be made from the fluid in case one finds on microscopical examination echinococcus hooks or portions of a cyst-wall.

Fig. 306.

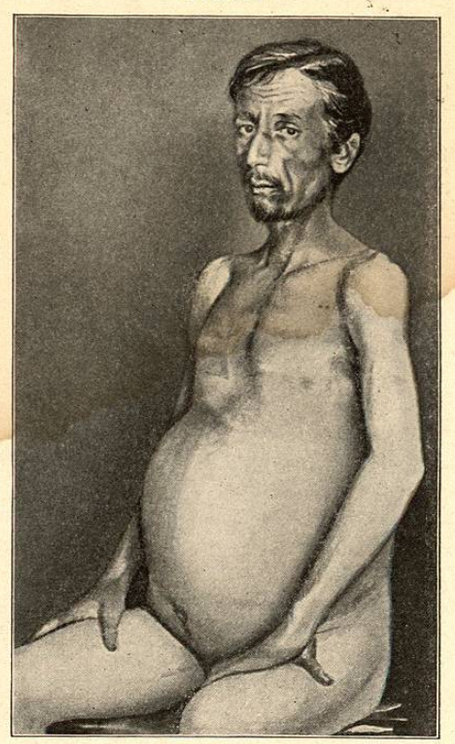

Patient suffering from a large hydatid cyst of the liver. (Lancereaux.)

Special Pathology.—Usually one finds only a single echinococcus cyst in the liver, two or more being present according to Könitzer in 12.6 per cent. of the cases. The right lobe is usually affected. If the cyst is situated in the centre of the liver, the shape of the organ is little changed. It may undergo great changes if the cyst or cysts are near the periphery. In some instances, especially if the cyst is near the lower surface, the suspected portion of the liver may become pedicled, rendering diagnosis extremely difficult. Sometimes the cyst

Fig. 307.

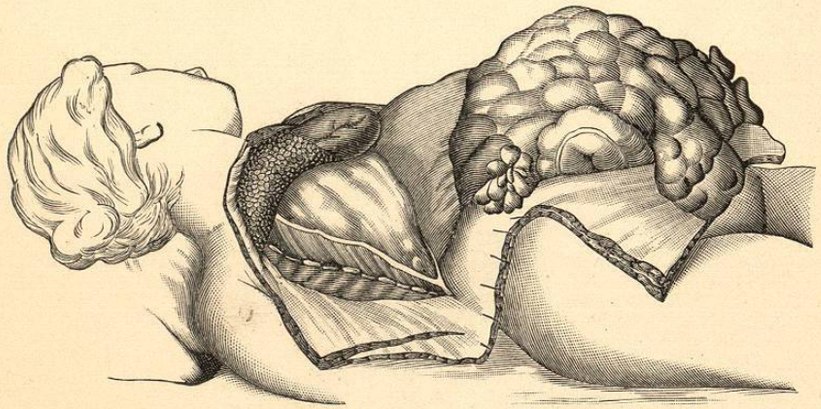

Hydatid cyst of the upper portion of the liver and multiple cysts of the omentum. (Lancereaux.)

grows until it reaches the pelvis; or, if situated upon the upper surface, it may press the diaphragm upward until the right lung is reduced

Fig. 308.

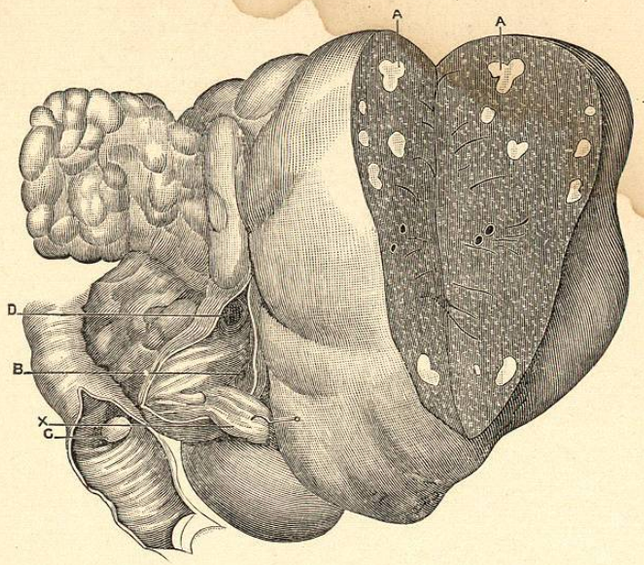

Large hydatid cyst of the left lobe of the liver and multiple abscesses of the right lobe, *a*, *a*; *d*, cyst breaking into the common duct; *c*, ampulla of Vater. (Lancereaux.)

to the size of an egg. Usually, however, it produces a rounded swelling in the right hypochondrium or epigastrium, while the rest of the liver is unaltered. The tissue immediately over the cyst suffers

atrophy through compression, and compression of the larger biliary ducts may cause jaundice. This is a rare symptom, for the reason that the slow growth of the cyst permits the ducts to accommodate themselves to the altered relations. Traumatism may rupture the cyst. Bacteria may enter it and set up suppuration. The clear fluid in it will then be changed into a cloudy one and then into foul pus. The echinococcus may die before infection takes place. In such a case the cyst contracts and its contents calcify or change into a grumous fluid.

Fig. 309.

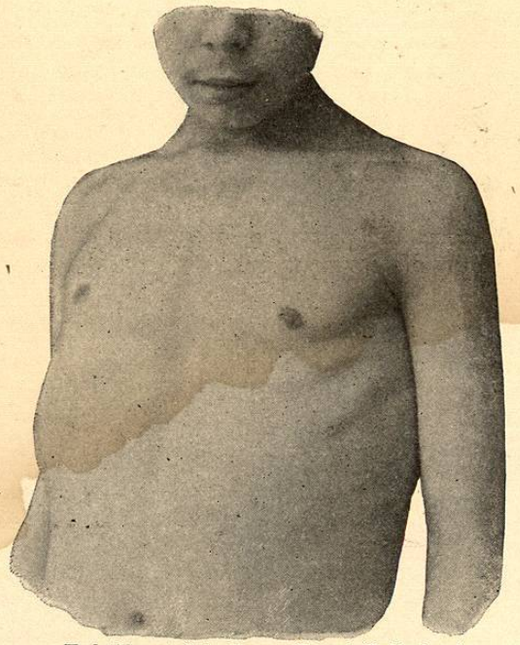

Hydatid cyst of the liver. (Francis H. Markoe.)

The cyst may press upon the portal vein and cause ascites, or it may press upon the vena cava; or it may interfere with the normal functions of the stomach or intestine. It may rupture into the pleural cavity and then into the bronchi with spontaneous recovery, or death, as the case may be. Perforation into the portal vein, the hepatic vein, the inferior vena cava, the hepatic artery or the pulmonary artery, into the pelvis of the kidney or the urinary bladder is rare. Perforation into a bile-duct is relatively more common. The cysts may be discharged through the common duct or they may block this up, giving the symptoms of stenosis. Sterile bile may terminate the life of the echinococcus without especial symptoms, whereas if infection is added there will be the usual symptoms of pain, fever, etc. Perforation into the stomach or intestine if preceded by adhesions is a favorable outcome. Perforation into the free peritoneal cavity is most

unfavorable. Perforation through the skin is the most favorable of all. An echinococcus cyst has been known to perforate in two directions.

Symptoms.—Echinococcus of the liver as long as it is small produces scarcely any symptoms. Pain is slight and jaundice is rarely seen. The patient begins to complain when the cyst is sufficiently large to press upon some neighboring organ. If the cyst suppurates, there will be chills and high fever, intense pain in the region of the liver, emaciation, and loss of strength. The cyst may from time to time press upon the kidney and produce an intermittent albuminuria. If the cyst presses against the diaphragm, there will be dyspnœa, cough, and a feeling of anxiety due to pressure upon the heart. Intense pain in the side and gasping for breath precede rupture into the pleural cavity. The result is an acute inflammation which is usually fatal, although spontaneous recovery may follow if the fluid perforates the lung and is discharged through the bronchi. If the lung becomes adherent to the diaphragm before perforation takes place, the symptoms will be those of chronic pneumonia, and a correct diagnosis will probably not be made until the cysts are coughed up. Such a patient may recover, but he runs the risk of death from suffocation in his attempts to cough up the cysts. Rupture into the peritoneal cavity produces speedy death if the cyst contents are purulent. If not, there will follow symptoms of poisoning due to the resorption of toxins and ptomaïns. The skin of such a patient breaks out in a rash similar to urticaria, a point of importance in the diagnosis. If adhesions have formed, so that the rupture is into a small cavity, the prognosis is more favorable. Rupture into the biliary passages produces cholangitis if the echinococcus cyst contains pus and its contents are not rapidly discharged into the intestine. Rupture into the stomach or intestine is preceded by the symptoms of circumscribed peritonitis, namely, pain, loss of appetite, and disturbances of digestion. If rupture occurs into the urinary passages, a cyst may stick in the ureter and cause obstruction. Rupture through the skin is characterized by the presence of tortuous fistulas which show little tendency to heal.

If the echinococcus dies, many of the symptoms may still persist.

Diagnosis.—Diagnosis of echinococcus cyst is impossible as long as the tumor is small. When the tumor is recognized, it appears connected with the liver, rounded, with a smooth surface, elastic, and possibly distinctly fluctuating. If the tension within the cyst is very high, fluctuation cannot be made out and the tumor appears solid. If there is no inflammation, there will be no tenderness on pressure. The tumor moves with respiration just as does the liver. It is completely dull on percussion, and if the patient is put in such a position that the abdominal muscles are relaxed, the situation, extent, mobility, consistence, and configuration of the tumor can usually be made out by palpation. The so-called hydatid tremor said to be characteristic of echinococcus is rarely found. Moreover, it may also occur in hydronephrosis, ascites, or cystosarcoma of the liver.

Echinococcus is differentiated with difficulty from cysts of a non-parasitic nature. An exploratory puncture has in many instances cleared the diagnosis, but this is a method which ought never to be resorted to. The tension in an echinococcus sac is so high that fluid may easily trickle into the peritoneal cavity through the opening made by the finest trocar. If the cyst is suppurating, peritonitis will speedily follow such an accident. Even if the cyst is sterile, puncture has been repeatedly followed by serious symptoms of poisoning produced by the toxins and the fluid, and by a general development of echinococcus cysts throughout the peritoneal cavity. For these reasons puncture should never be made; or it should at least be followed by immediate laparotomy.

The diagnosis of suppurating echinococcus is easy if the patient is known to have had a tumor with the characteristics of echinococcus before suppuration took place. The symptoms of pain, fever, and peritoneal irritation will then be added to those previously existing. The symptoms of inflammation are less marked if the tumor becomes adherent to the external abdominal wall and threatens to break through the skin; but even then redness and the peculiar condition of the skin and subcutaneous tissues and some general symptoms will reveal the true state of affairs. It should not be forgotten that when several cysts exist one may suppurate while the others still contain clear contents.

Abscess of the liver may usually be distinguished from suppurating echinococcus cyst by the history of previous colic and other symptoms due to gall-stones or traumatism. Carcinoma of the liver has a rough surface and feels harder than echinococcus. In fatty liver and amyloid disease the organ is uniformly enlarged and the history of the case will usually serve for a differentiation of these diseases. Hydrops of the gall-bladder produces a rounded tumor, but here too there will usually be a history of colic and symptoms due to gall-stones. A pedicled echinococcus cyst is most likely to be mistaken for a distended gall-bladder. Hydronephrosis or pyonephrosis of the right kidney is oval and extends well downward. Cysts of the spleen, pancreas, and mesentery have often been confounded with echinococcus of the liver, usually because of insufficient attention to the history of the case and the examination of the patient. An exact diagnosis is, moreover, not of the greatest importance since both conditions require treatment by laparotomy. Still, it is desirable to know the exact object of operation if possible before it is undertaken.

Subphrenic abscess and pleurisy with effusion are sometimes distinguished from subphrenic echinococcus with difficulty. In such circumstances exploratory puncture would be of great service, but for the reasons given above it is dangerous. If it is suspected that pus has collected either above or beneath the diaphragm, and puncture is necessary to confirm the diagnosis or to prove its correctness to the friends of the patient, this should be performed with aseptic precautions. If a clear fluid is obtained, operation should follow puncture

and the canula should be left in place. Meanwhile one should make it a practice to establish the diagnosis without puncture. Thus pleurisy develops suddenly with marked symptoms—fever, pain in the side, etc.; subphrenic echinococcus develops gradually and without marked symptoms. The pain of echinococcus is general in the whole right side, whereas that of pleurisy is well localized. The dyspnœa of echinococcus is constant; that of pleurisy exists only in the beginning of the affection. Pleurisy with effusion distends the whole side of the thorax, while the swelling of subphrenic echinococcus affects chiefly the lower portion of the chest. A pleural exudate fills the intercostal spaces and possibly causes them to bulge outward; this is never true of echinococcus. A pleural exudate presses the liver downward; the effect upon the liver of subphrenic echinococcus varies according to its situation: if it is posterior, the margin of the liver remains in its normal position. Finally, the course of echinococcus is a very slow one, while that of suppurative pleurisy is far more rapid.

If the suppurating echinococcus cyst is situated just beneath the diaphragm, it can easily be mistaken for a right pyothorax. A differential diagnosis between these two conditions is given under Subphrenic Abscess.

A distinction between subphrenic echinococcus and echinococcus within the pleural cavity is extremely important since the treatment is radically different. In the first place, the presence or absence of pleural exudate is to be determined. If the history shows there has been no acute attack, that dyspnœa is present and marked, that the respiratory murmur in the compressed lung is clearly vesicular and sharply differentiated from the area which is dull on percussion, and if the line between these areas does not alter with changes in the position of the patient, there is good reason to exclude exudate and to accept the diagnosis of echinococcus. If the disease is above the diaphragm, the distention of the thorax is more barrel-shaped rather than bell-shaped; the liver is pushed further downward and follows the motions of respiration more quickly than when the disease is below the diaphragm, since the action of the diaphragm is less interfered with.

If the echinococcus of the liver perforates into the peritoneal cavity, as a result usually of traumatism, the tumor disappears and there follow symptoms of intense peritoneal irritation (collapse, pain, fever, distention of the abdomen, etc.). If urticaria develops, the diagnosis is complete. If the patient survives the rupture, he may suffer from the development of echinococcus throughout the peritoneal cavity with the production of cystic tumors of varying size.

Echinococcus of the liver is a disease which may last from two to thirty years. Madelung believes that infection usually takes place in childhood even when the tumor does not become noticeable until adult life. The symptoms vary greatly according as the echinococcus maintains its vitality or dies, or the cyst suppurates, or ruptures. Rupture into the peritoneal cavity has a mortality of about 90 per cent.; that through the skin, a mortality of 10 per cent.; while the mortality of rupture