the iris. It is composed of connective tissue, muscular fibres of the non-striated variety, many blood-vessels, and probably nerve-terminations. Directly surrounding the pupil, forming a band about $\frac{1}{50}$ of an inch (0·5 mm.) in width, is a layer of non-striated muscular fibres, called the sphincter of the iris. The existence of these fibres is admitted by all anatomists. It is different, however, for the radiating muscular fibres. Most anatomists describe, in addition to the sphincter, non-striated fibres, which can be traced from near the great circumference of the iris almost to its pupillary border, lying both in front of and behind the circular fibres. A few observers deny that these fibres are muscular; but they recognize a thick, muscular layer surrounding the arteries of the iris. This is merely a question of observation; but the weight of anatomical authority is in favor of the existence of the radiating fibres, and their presence explains certain of the phenomena of dilatation of the iris which would otherwise be difficult to understand.

The blood-vessels of the iris are derived from the arteries of the choroid, from the long posterior ciliary and from the anterior ciliary arteries. The long ciliary arteries are two branches, running along the sides of the eyeball, between the sclerotic and choroid, to form finally a circle surrounding the iris. The anterior ciliary arteries are derived from the muscular branches of the ophthalmic. They penetrate the sclerotic, a little behind the iris, and join the long ciliary arteries, in the vascular circle. From this circle, the vessels branch and pass into the iris, to form a smaller arterial circle around the pupil. The veins from the iris empty into a circular sinus situated at the junction of the cornea with the sclerotic. This is sometimes spoken of as the circular venous sinus, or the canal of Schlemm.

The nerves of the iris are the long ciliary, from the fifth cranial, and the short ciliary, from the ophthalmic ganglion.

Pupillary Membrane.—At a certain period of fœtal life the pupil is closed by a membrane connected with the lesser circumference of the iris, called the pupillary membrane. This is not distinct during the first months; but between the third and the fourth months, it is readily seen. It is most distinct at the sixth month. The membrane is thin and transparent, and it completely separates the anterior from the posterior chamber of the eye. It is provided with vessels derived from the arteries of the iris, anastomosing with each other and turning back in the form of loops near the centre. At about the seventh month, it begins to give way at the centre, gradually atrophies, and scarcely a trace of it can be seen at birth.

Retina.—The retina is described by anatomists as the third tunic of the eye. It is closely connected with the optic nerve, and the most important structures entering into its composition are probably continuous with prolongations from the nerve-cells. This is the membrane endowed with the special sense of sight, the other structures in the eye being accessory.

If the sclerotic and choroid be removed from the eye under water, the retina is seen, in perfectly fresh specimens, in the form of a delicate, transparent membrane covering the posterior portion of the vitreous humor. A short time after death it becomes slightly opaline. It extends over the pos-

terior portion of the eyeball, to a distance of about $\frac{1}{15}$ of an inch (1·7 mm.) behind the ciliary processes. When torn from its anterior attachment, it presents a finely serrated edge, called the ora serrata. This edge adheres very closely, by mutual interlacement of fibres, to the zone of Zinn. In the middle of the membrane, its thickness is about $\frac{1}{120}$ of an inch (200 μ). It becomes thinner nearer the anterior margin, where it measures only about $\frac{1}{300}$ of an inch (80 μ). Its external surface is in contact with the choroid, and its internal, with the hyaloid membrane of the vitreous humor.

The optic nerve penetrates the retina about $\frac{1}{8}$ of an inch (3·2 mm.) within and $\frac{1}{12}$ of an inch (2·1 mm.) below the antero-posterior axis of the globe, presenting at this point a small, rounded elevation upon the internal surface of the membrane, perforated in its centre for the passage of the central artery of the retina. At a point $\frac{1}{12}$ to $\frac{1}{8}$ of an inch (2·1 to 3·2 mm.) external to the point of penetration of the nerve, is an elliptic spot, its long diameter being horizontal, about $\frac{1}{8}$ of an inch (2·1 mm.) long and $\frac{1}{36}$ of an inch (0·7 mm.) broad, called the yellow spot of Sömmerring, or the macula lutea. In the centre of this spot, is a depression, called the fovea centralis. This depression is exactly in the axis of distinct vision. The yellow spot exists only in man and the quadrumana.

The structures in the retina which present the greatest physiological importance are the external layer, formed of rods and cones, the layer of nerve-cells, and the filaments which connect the rods and cones with the cells. These are the only anatomical elements of the retina, as far as is known, except the pigment cells, that are directly concerned in the reception of optical impressions, and they will be described rather minutely, while the intermediate layers will be considered more briefly.

Most anatomists recognize nine layers in the retina:

1. Layer of pigment-cells (already described in connection with the choroid).
2. Jacob's membrane, the bacillar membrane, or the layer of rods and cones.
3. The external granule-layer.
4. The inter-granule layer (cone-fibre plexus of Hulke).
5. The internal granule-layer.
6. The granular layer.
7. The layer of nerve-cells (ganglion-layer).
8. The expansion of the fibres of the optic nerve.
9. The limitary membrane.

The layer of rods and cones is composed of rods, or cylinders, extending through its entire thickness, closely packed, and giving to the external surface a regular, mosaic appearance; and between these, are a greater or less number of flask-shaped bodies, the cones. This layer is about $\frac{1}{330}$ of an inch (76 μ) in thickness at the middle of the retina; $\frac{1}{400}$ of an inch (62 μ), about midway between the centre and the periphery; and near the periphery, about $\frac{1}{450}$ of an inch (55 μ). At the macula lutea the rods are wanting, and the layer is composed entirely of cones, which are here very much elongated.

Over the rest of the membrane the rods predominate, and the cones become less and less frequent toward the periphery.

The rods are regular cylinders, their length corresponding to the thickness of the layer, terminating above in truncated extremities, and below in points which are probably continuous with the filaments of connection with the nerve-cells. Their diameter is about $\frac{1}{13000}$ of an inch (2 μ). They are clear, of rather a fatty lustre, soft and pliable, but somewhat brittle, and so alterable that they are with difficulty seen in a natural state. They should be examined in perfectly fresh preparations, moistened with liquid from the vitreous humor or with serum. When perfectly fresh it is difficult to make out any thing but an entirely homogeneous structure; but shortly after death each rod seems to be divided by a delicate line into an outer and an inner segment, the outer being a little the longer. At the upper extremity of the inner segment, is a hemispherical body, with its convexity presenting inward, called the lentiform body (*linsenförmiger Körper*). The entire inner segment is somewhat granular, and it often presents a granular nucleus at its inner extremity. The outer segment apparently differs in its constitution from the inner segment and is not similarly affected by reagents. Treated with dilute acetic acid, the outer segment becomes broken up transversely into thin disks.

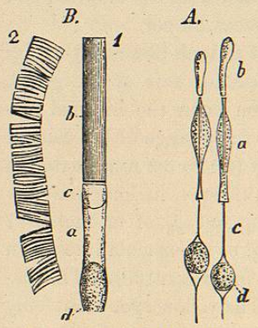

FIG. 246.—*Rods of the retina* (Schultze).

From the monkey.—*A*. Rods, after maceration in iodized serum, the outer segment (*b*) truncated, the inner segment (*a*) coagulated, granular, and somewhat swollen; *c*, filament of the rods; *d*, nucleus.

B. Rods from the frog: 1. Fresh, magnified 500 diameters; *a*, inner segment; *b*, outer segment; *c*, lentiform body; *d*, nucleus. 2. Treated with dilute acetic acid and broken up into plates.

The cones are probably of the same constitution as the rods, but that portion called the inner segment is pyriform. The straight portion above (the outer segment) is sometimes called the cone-rod. The entire cones are about half the length of the rods and occupy the inner portion of the layer. The outer segment is in its constitution precisely like the outer segment of the rods. The inner segment is slightly granular and contains a nucleus. The cones are connected below with filaments passing into the deeper layers of the retina. The arrangement of the rods and cones is seen in Fig. 247, which shows the different layers of the retina.

At the fovea centralis, Jacob's membrane is composed entirely of elongated cones, with no rods. These are slightly increased in thickness at the macula lutea, but are diminished again in thickness, by about one-half, at the fovea centralis. At the fovea the optic nerve-fibres are wanting; and the ganglion-cells, which exist in a single layer over other portions of the retina, here present six to eight layers, except at the very centre, where there are but three layers. Of the layers between the cones and the ganglion cells, the external granule-layer and the inter-granule layer (cone-fibre plexus) remain, in the fovea, while the internal granule-layer and the granular layer are wanting. At the fovea, indeed, those elements of the retina which may be

regarded as purely accessory disappear, leaving only the structures that are concerned directly in the reception of visual impressions.

The external granule-layer is composed of large granules, looking like cells, which are each nearly filled with a single nucleus. These are connected with the filaments from the rods and cones. They are rounded or ovoid and measure from $\frac{1}{13000}$ to $\frac{1}{6000}$ of an inch (2 to 4 μ) in diameter. The inter-granule layer (cone-fibre plexus) is composed apparently of minute fibrillæ and a few nuclei. The internal granule-layer is composed of cells nearly like those of the external granule-layer, but a little larger, and prob-



FIG. 247.—*Vertical section of the retina* (H. Müller).

FIG. 248.—*Connection of the rods and cones of the retina with the nervous elements* (Sappey).

FIG. 247.—1, 1, layer of rods and cones; 2, rods; 3, cones; 4, 4, 5, 6, external granule-layer; 7, inter-granule layer (cone-fibre plexus); 8, internal granule-layer; 9, 10, finely granular, gray layer; 11, layer of nerve-cells; 12, 12, 12, 12, 14, 14, fibres of the optic nerve; 13, membrana limitans. (The pigmentary layer is not shown in this figure.)

FIG. 248.—1, 1, 2, 3, rods and cones, front view; 4, 5, 6, rods, side view; 7, 7, 8, 8, cells of the external and internal granule-layers; 9, cell, connected by a filament with subjacent cells; 10, 13, nerve-cells connected with cells of the granule-layers; 11, 21, filaments connecting cells of the external and internal granule-layers (12 is not in the figure); 14, 15, 16, 17, 18, 19, 20, 22, 23, 24, 25, 26, a rod and a cone, connected with the cells of the granule-layers, with the nerve-cells and with the nerve-fibres.

ably connected with the filaments of the rods and cones. The granular layer is situated next the layer of ganglion-cells.

The layer of ganglion-cells is composed of multipolar nerve-cells, measuring $\frac{1}{3000}$ to $\frac{1}{750}$ of an inch (8 to 32 μ) in diameter. In the centre of the retina, at the macula lutea, the cells present eight layers, and they diminish to a single layer near the periphery. The smaller cells are situated near the cen-

tre, and the larger, near the periphery. Each cell sends off several filaments (two to twenty-five), probably going to the layer of rods and cones, and a single filament which becomes continuous with one of the filaments of the optic nerve.

The layer formed by the expansion of the optic nerve is composed of pale, transparent nerve-fibres, $\frac{1}{50000}$ to $\frac{1}{25000}$ of an inch (0·5 to 1 μ) in diameter. These do not require special description.

The limitary membrane is a delicate structure, with fine striæ and nuclei; composed of connective-tissue elements. It is about $\frac{1}{25000}$ of an inch (1 μ) in thickness. From this membrane, connective-tissue elements are sent into the various layers of the retina, where they form a framework for the support of the other structures.

The retina becomes progressively thinner from the centre to the periphery. The granular layers and the nervous layers rapidly disappear in the anterior half of the membrane.

The following is the probable mode of connection between the rods and cones and the ganglion-cells: The filaments from the bases of the rods and cones pass inward, presenting in their course the corpuscles which have been described in the granule-layers, and finally become, as is thought, directly continuous with the poles of the ganglion-cells. The cells send filaments to the layer formed by the expansion of the optic nerve, which are continuous with the nerve-fibres. This arrangement is shown in Fig. 248.

The following description of the blood-vessels of the retina, with Fig. 249, was furnished by Loring:

"The arteries and veins of the retina are subdivisions of the arteria and vena centralis. The larger branches run in the nerve-fibre layer and are immediately beneath the limitary membrane. The vessels lie so superficially that in a cross-section examined with the microscope, they are seen to project above the general level of the retina, toward the vitreous humor. While the large vessels are in the plane of the inner surface of the retina, the smaller branches penetrate the substance of the retina, to the inter-granule layer. They do not extend, however, as far as the external granule-layer and the layer of rods and cones. These two layers, therefore, have no blood-vessels.

"The ramifications of the vessels present a beautifully arborescent appearance when seen with the ophthalmoscope. The manner in which the vessels are distributed and the way in which the circulation is carried on can be better understood by a study of Fig. 249 than by any detailed description. The figure represents the ophthalmoscopic appearance of a normal eye in young, adult life. The darker vessels are the veins, and the lighter vessels, the arteries. The dotted oval line is diagrammatic and marks the position and extent of the macula lutea. It is seen that this oval space contains a number of fine vascular twigs which, coming from above and below, extend toward the spot in the centre of the oval which marks the position of the fovea centralis. In opposition, then, to the general opinion, which is that

the macula lutea has no blood-vessels, it is the spot of all others in the retina which is most abundantly supplied with minute vascular branches. These vessels can be distinctly seen even with the ophthalmoscope; and microscopical examination shows that the capillary plexus in the macula lutea is closer and richer than in any other part of the retina."

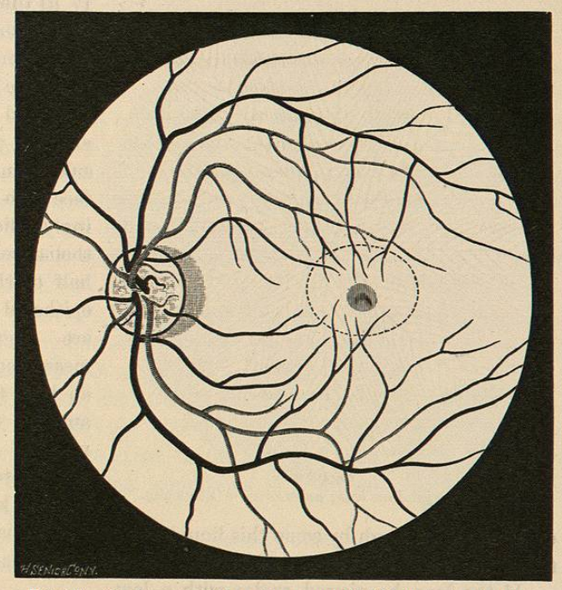

FIG. 249.—*Blood-vessels of the retina; magnified 7½ diameters* (Loring).

The arteries of the retina send branches to the periphery, where they supply a wide plexus of very small capillaries in the ora serrata. These capillaries empty into an incomplete venous circle, branches from which pass back by the sides of the arteries, to the vena centralis.

Crystalline Lens.—The crystalline is a double-convex lens, which is perfectly transparent and very elastic. Its action in the refraction of the rays of light is analogous to that of convex lenses in optical instruments. It is situated behind the pupil, in what is called the hyaloid fossa of the vitreous humor, which is exactly moulded to its posterior convexity. In the fœtus the capsule of the lens receives a branch from the arteria centralis, but it is non-vascular in the adult. The anterior convexity of the lens is just behind the iris, and its borders are in relation with what is known as the suspensory ligament. The convexities do not present regular curves, and they are so subject to variations after death that the measurements, post mortem, are of little value. During life, however, they have been measured very exactly in the various conditions of accommodation. The diameters of the lens in the adult are about $\frac{1}{3}$ of an inch (8·5 mm.) transversely and $\frac{1}{4}$ of an inch (6·4 mm.) antero-posteriorly. The convexity is greater on its posterior than on its anterior surface. In fœtal life the convexities of the lens are greater than in the adult and its structure is much softer. In old age the convexities are diminished and the lens becomes harder and less elastic. The substance of the lens is made up of layers of fibres of different degrees of density, and the whole is enveloped in a delicate membrane, called the capsule.

The capsule of the lens is a thin, transparent membrane, which is very elastic. This membrane generally is from $\frac{1}{2500}$ to $\frac{1}{1500}$ of an inch (10 to 17 μ) thick; but it is very thin at the periphery, measuring here only $\frac{1}{6000}$ of an inch (4 μ). Its thickness is increased in old age. The anterior portion of the capsule is lined on its inner surface with a layer of exceedingly delicate, nucleated epithelial cells. The posterior half of the capsule has no epithelial lining. The cells are regularly polygonal, measuring $\frac{1}{2000}$ to $\frac{1}{1250}$ of an inch (12 to 20 μ) in diameter, with large, round nuclei. After death, they are said to break down into a liquid, known as the liquid of Morgagni, though by some this liquid is supposed to be exuded from the substance of the lens. At all events, the cells disappear soon after death.

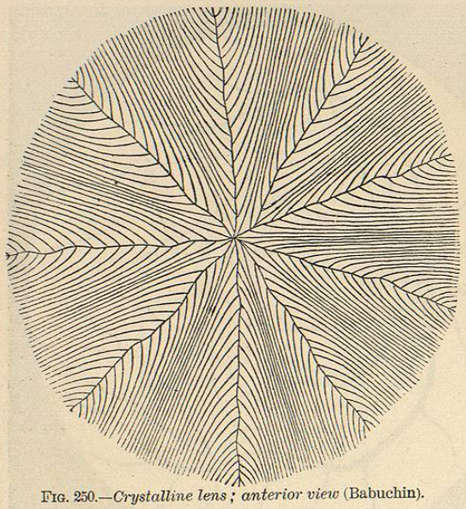

Fig. 250.—*Crystalline lens; anterior view* (Babuchin).

If the lens be viewed entire with a low magnifying power, it presents upon either of its surfaces, a star with nine to sixteen radiations extending from the centre to about half or two-thirds of the distance to the periphery. The stars seen upon the two surfaces are not coincident, the rays of one being situated between the rays of the other. In the fœtus the stars are more simple, presenting only three radiations upon either surface. These stars are not fibrous, like the rest of the lens, but are composed of a homogeneous substance, which extends, also, between the fibres.

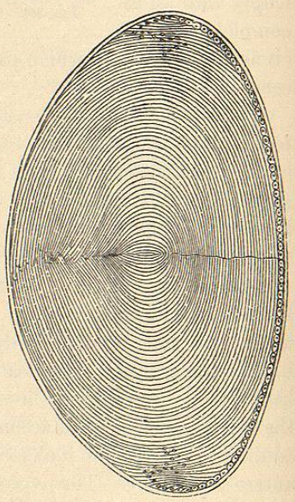

Fig. 251.—*Section of the crystalline lens* (Babuchin).

The greatest part of the substance of the lens is composed of very delicate, soft and pliable fibres, which are transparent, but perfectly distinct. These fibres are flattened, six-sided prisms, closely packed together, so that their transverse section presents a regularly tesselated appearance. They are $\frac{1}{5000}$ to $\frac{1}{2500}$ of an inch (5 to 10 μ) broad, and $\frac{1}{13000}$ to $\frac{1}{9000}$ of an inch (2 to 3 μ) in thickness. Their flat surfaces are parallel with the surface of the lens. The direction of the fibres is from

the centre and from the rays of the stellate figures to the periphery, where they turn and pass to the star upon the opposite side. The outer layers of fibres near the equator, or circumference of the lens, contain exceedingly distinct, oval nuclei, with one or two nucleoli. These become smaller in passing more deeply into the substance of the lens, and gradually they disappear.

The regular arrangement of the fibres of the lens makes it possible to separate its substance into laminæ, which have been compared by anatomists to the layers of an onion; but this separation is entirely artificial, and the number of apparent layers depends upon the dexterity of the manipulator. It is to be noted, however, that the external portions of the lens are soft, even gelatinous, and that the central layers are much harder, forming a sort of central kernel, or nucleus.

The lens is composed of a nitrogenized substance, called crystalline, combined with various inorganic salts. One of the constant constituents of this body is cholesterine. In an examination of four fresh crystalline lenses of the ox, cholesterine was found in the proportion of 0·907 of a part per 1,000 (Flint). In some cases of cataract cholesterine exists in the lens in a crystalline form; but under normal conditions it is united with the other constituents.



Fig. 252.—*Zone of Zinn* (Sappey).
1, crystalline lens; 2, 2, vitreous humor; 3, 3, zone of Zinn; 4, 4, posterior portion of the zone of Zinn, thrown into folds; 5, 6, 6, anterior and middle portions of the zone of Zinn.

Suspensory Ligament of the Lens (*Zone of Zinn*).—The vitreous humor occupies about the posterior two-thirds of the globe, and is enveloped in a delicate capsule, called the hyaloid membrane. In the region of the ora serrata of the retina, this membrane divides into two layers. The posterior layer lines the depression in the vitreous humor into which the lens is received. The anterior layer passes forward toward the lens and divides into two secondary layers, one of which passes forward, to become continuous with the anterior portion of the capsule of the lens, while the other passes to the posterior surface of the lens, to become continuous with this portion of its capsule. The anterior of these layers is corrugated or thrown into folds which correspond with the ciliary processes, with which it is in contact. This corrugated portion is called the zone of Zinn. The two layers thus surround the lens and are properly called its suspensory ligament. As the two layers of the suspensory ligament separate at a certain distance from the lens, one passing to the anterior and the other to the posterior portion of the capsule, there remains a triangular canal, about $\frac{1}{10}$ of an inch (2·5 mm.) wide, surrounding the border of the lens, called the canal of Petit. Under natural conditions the walls of this canal are nearly in apposition, and it contains a very small quantity of clear liquid.

The membrane forming the suspensory ligament is composed of pale, longitudinal and transverse fibres of rather a peculiar appearance, which are much less affected by acetic acid than the ordinary fibres of connective tissue.

Aqueous Humor.—The space bounded in front by the cornea, posteriorly,

by the crystalline lens and the anterior face of its suspensory ligament, and at its circumference, by the tips of the ciliary processes, is known as the aqueous chamber. This contains a clear liquid called the aqueous humor. The iris separates this space into two divisions, which communicate with each other through the pupil; viz., the anterior chamber, situated between the anterior face of the iris and the cornea, and the posterior chamber, between the posterior face of the iris and the crystalline. It is evident, from the position of the iris, that the anterior chamber is much the larger; and, indeed, the posterior surface of the iris and the anterior surface of the lens are in contact, except, perhaps, near their periphery or when the iris is very much dilated. The liquid filling the chambers of the eye is rapidly reproduced after it has been evacuated, as occurs in many surgical operations upon the eye.

The aqueous humor is colorless and transparent, faintly alkaline, of a specific gravity of about 1005, and with the same index of refraction as that of the cornea and the vitreous humor. It contains a small quantity of an albuminoid matter, but it is not rendered turbid by heat or other agents which coagulate albumen. Various inorganic salts (the chlorides, sulphates, phosphates and carbonates) exist in small proportions in this liquid. It also contains traces of urea and glucose.

The anterior and posterior chambers of the eye are regarded as lymph-spaces communicating with the lymphatics of the conjunctiva, cornea, iris and ciliary processes. In addition a lymph-space is described as existing between the choroid and the sclerotic. This space is supposed to communicate with a perivascular canal-system around the vasa vorticosa, and through these vessels, with the space between the capsule of Tenon and the sclerotic (Schwalbe). The latter is connected with lymph-channels which surround the optic nerve (Key and Retzius).

Vitreous Humor.—The vitreous humor is a clear, glassy substance, occupying about the posterior two-thirds of the globe. It is enveloped in a delicate, structureless capsule, called the hyaloid membrane, which is about $\frac{1}{6000}$ of an inch ($4\ \mu$) in thickness. This membrane adheres rather strongly to the limitary membrane of the retina. In front, at the ora serrata, the hyaloid membrane is thickened and becomes continuous with the suspensory ligament of the lens.

The vitreous humor itself is gelatinous, of feeble consistence and slightly alkaline in its reaction, with a specific gravity of about 1005. Upon section there oozes from it a watery and slightly mucilaginous liquid. This humor is not affected by heat or alcohol, but it is coagulated by certain mineral salts, especially lead acetate. When thus solidified it presents regular layers, like the white of an egg boiled in its shell; but these are artificial. In the embryon the vitreous humor is divided into a number of little cavities and contains cells and leucocytes. It is also penetrated by a branch from the central artery of the retina, which passes through its centre, to ramify upon the posterior surface of the crystalline lens. This structure, however, is not found in the adult, the vitreous humor being then entirely without blood-

vessels. The vitreous humor is divided into compartments formed by delicate membranes radiating from the point of penetration of the optic nerve to the anterior boundary where the hyaloid membrane is in contact with the capsule of the lens. In this way the humor is divided up, something like the half of an orange, by about one hundred and eighty membranous processes of extreme delicacy, which do not interfere with its transparency.

Summary of the Anatomy of the Globe of the Eye.

This summary is intended simply to indicate the relations and the physiological importance of the various parts of the eye, in connection with Fig. 253.

The eyeball is nearly spherical in its posterior five-sixths, its anterior sixth

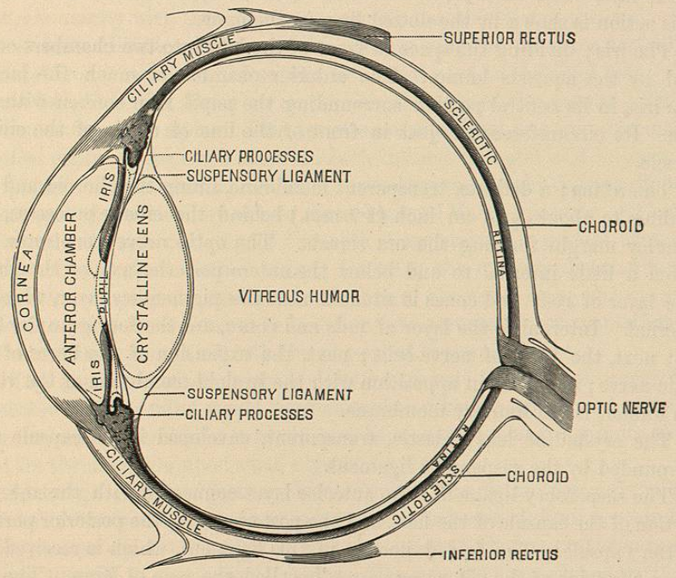

Fig. 253.—*Section of the human eye.*

being formed of the segment of a smaller sphere, which is slightly projecting. It presents the following parts, indicated in the figure.

The sclerotic; a dense, fibrous membrane, chiefly for the protection of the more delicate structures of the globe, and giving attachment to the muscles which move the eyeball. Attached to the sclerotic are the tendons of the recti and the oblique muscles.

The cornea; a transparent structure, forming the anterior, projecting sixth of the globe; dense and resisting, allowing, however, the passage of light; covered, on its convex surface, with several layers of transparent epithelial cells.

The choroid coat; lining the sclerotic and extending only as far forward.