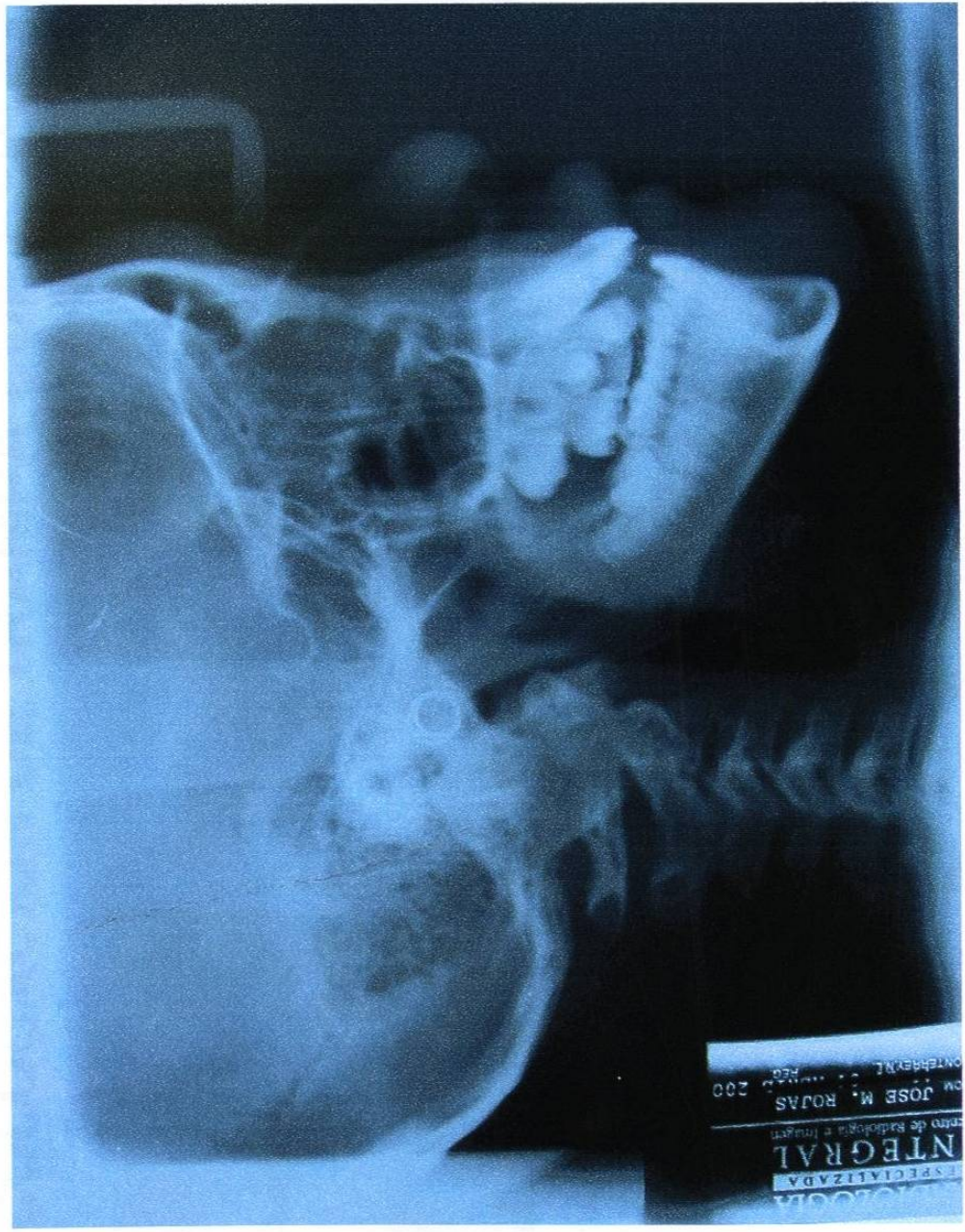
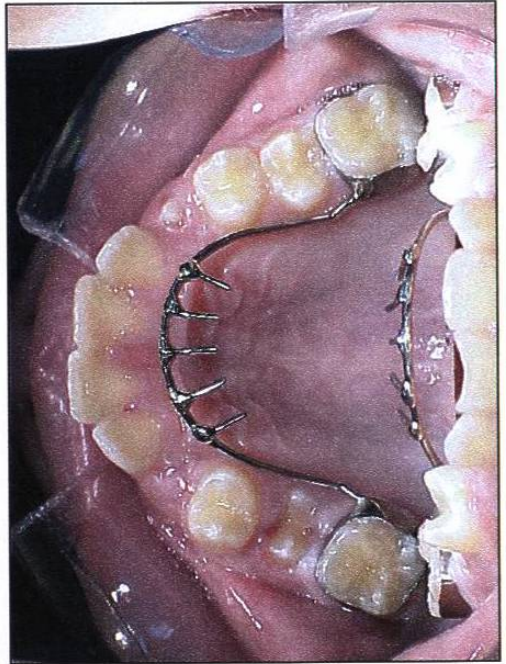
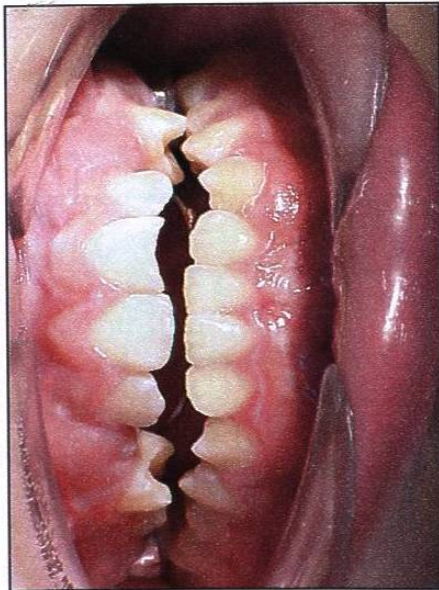
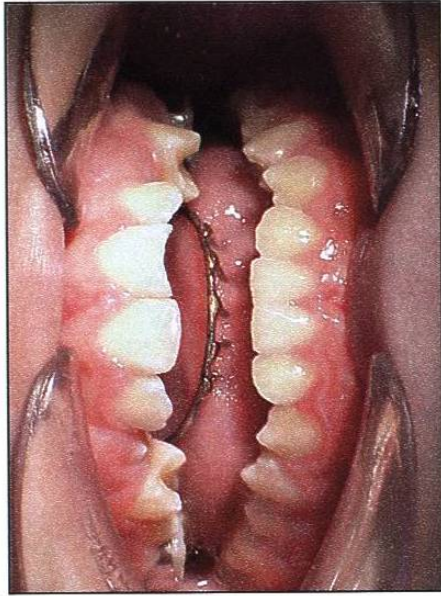


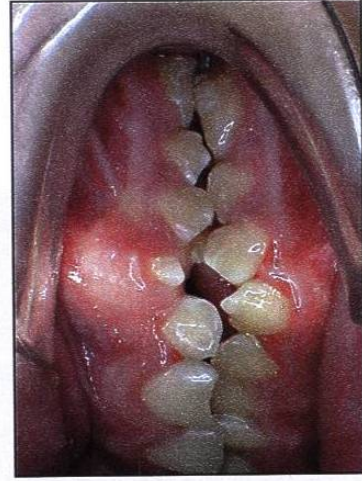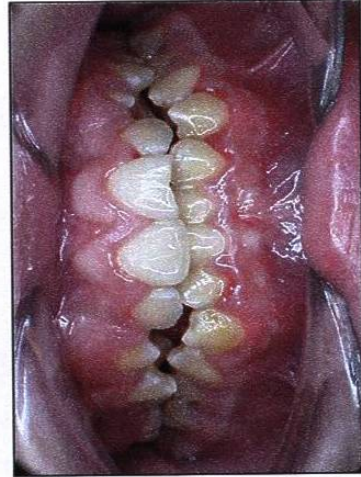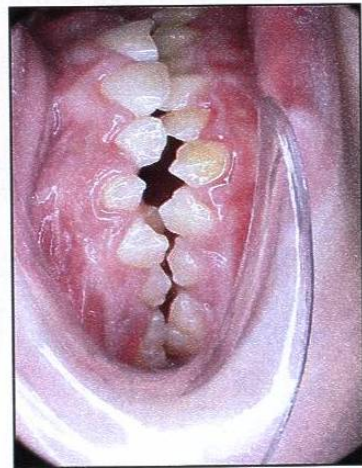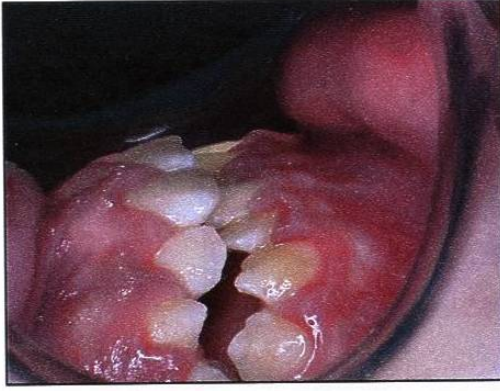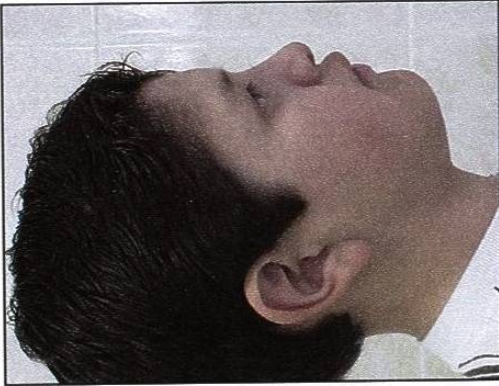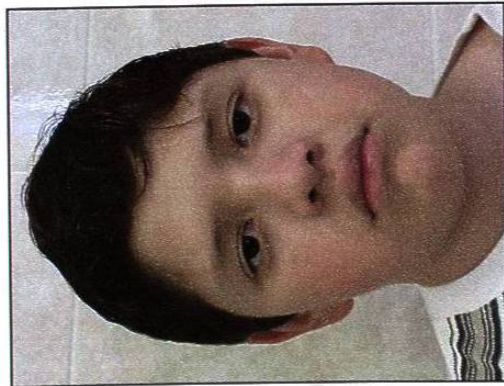CASO CLÍNICO 1
CEFALOGRAMA LATERAL INICIAL



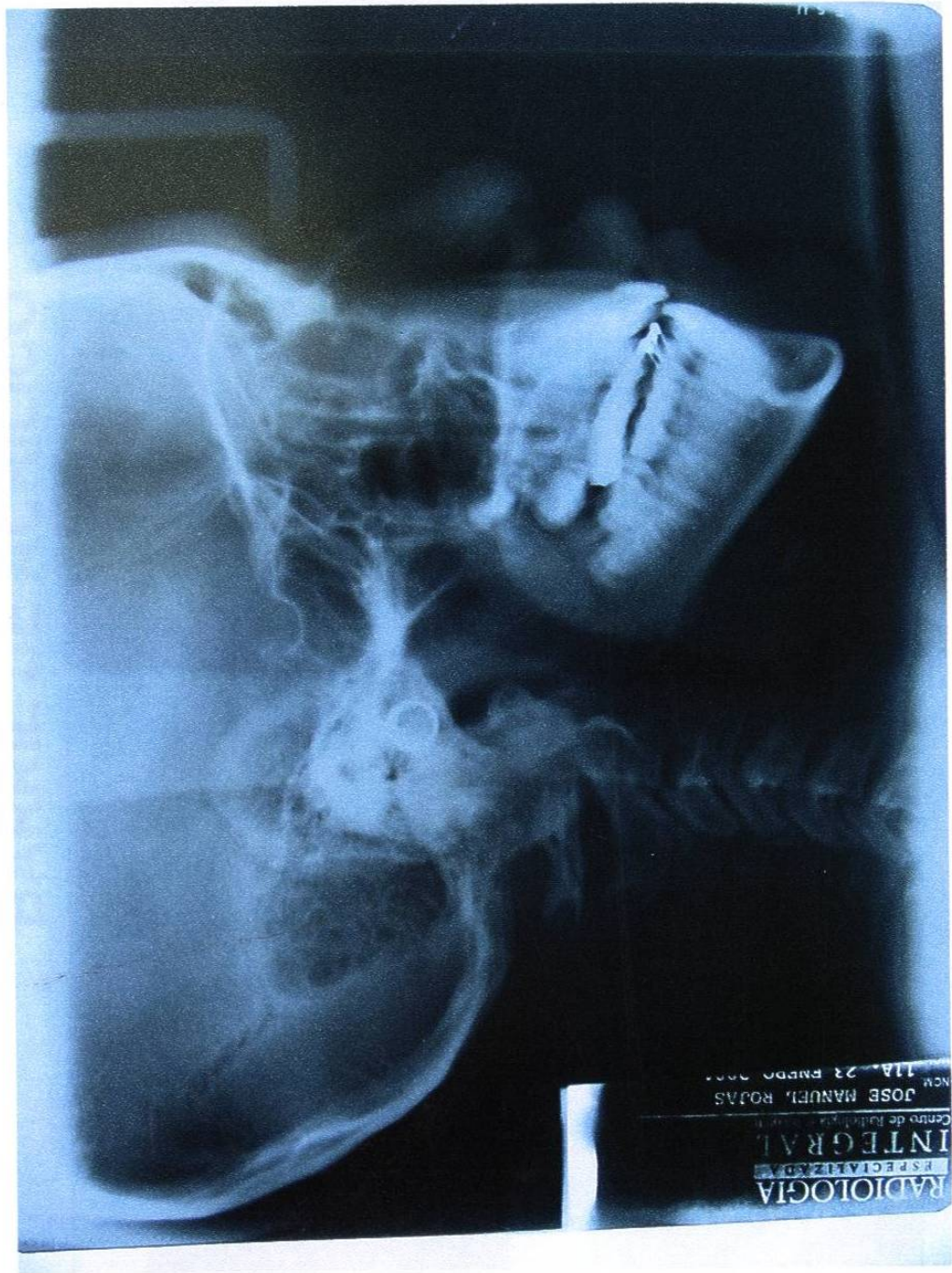CASO CLÍNICO 1 COLOCACIÓN DE TRAMPA CON ESPOLONES



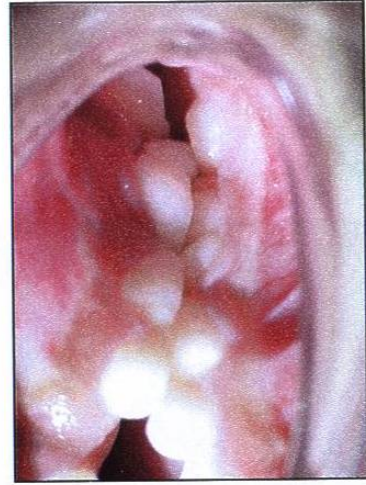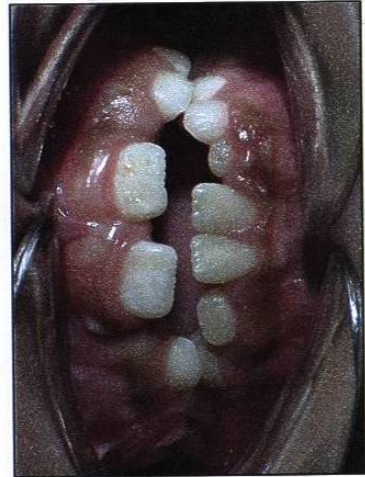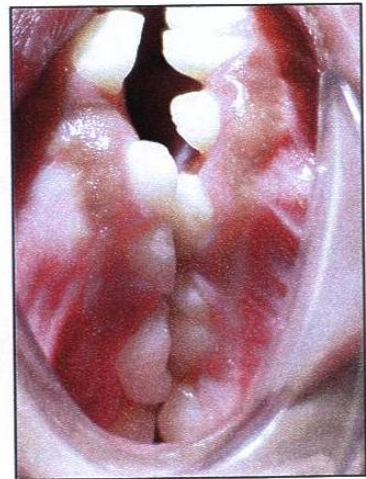
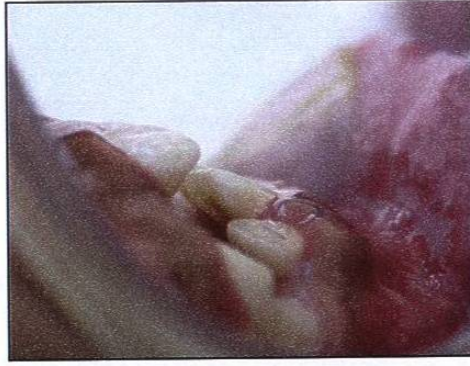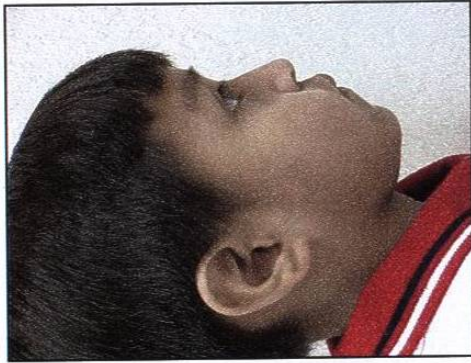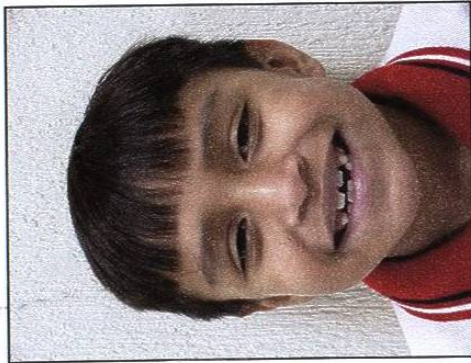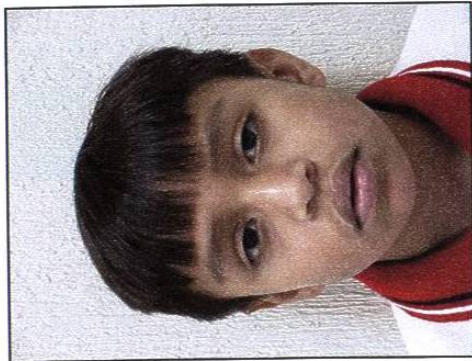CASO CLÍNICO 1
POST-TRATAMIENTO DE TRAMPA CON ESPOLONES



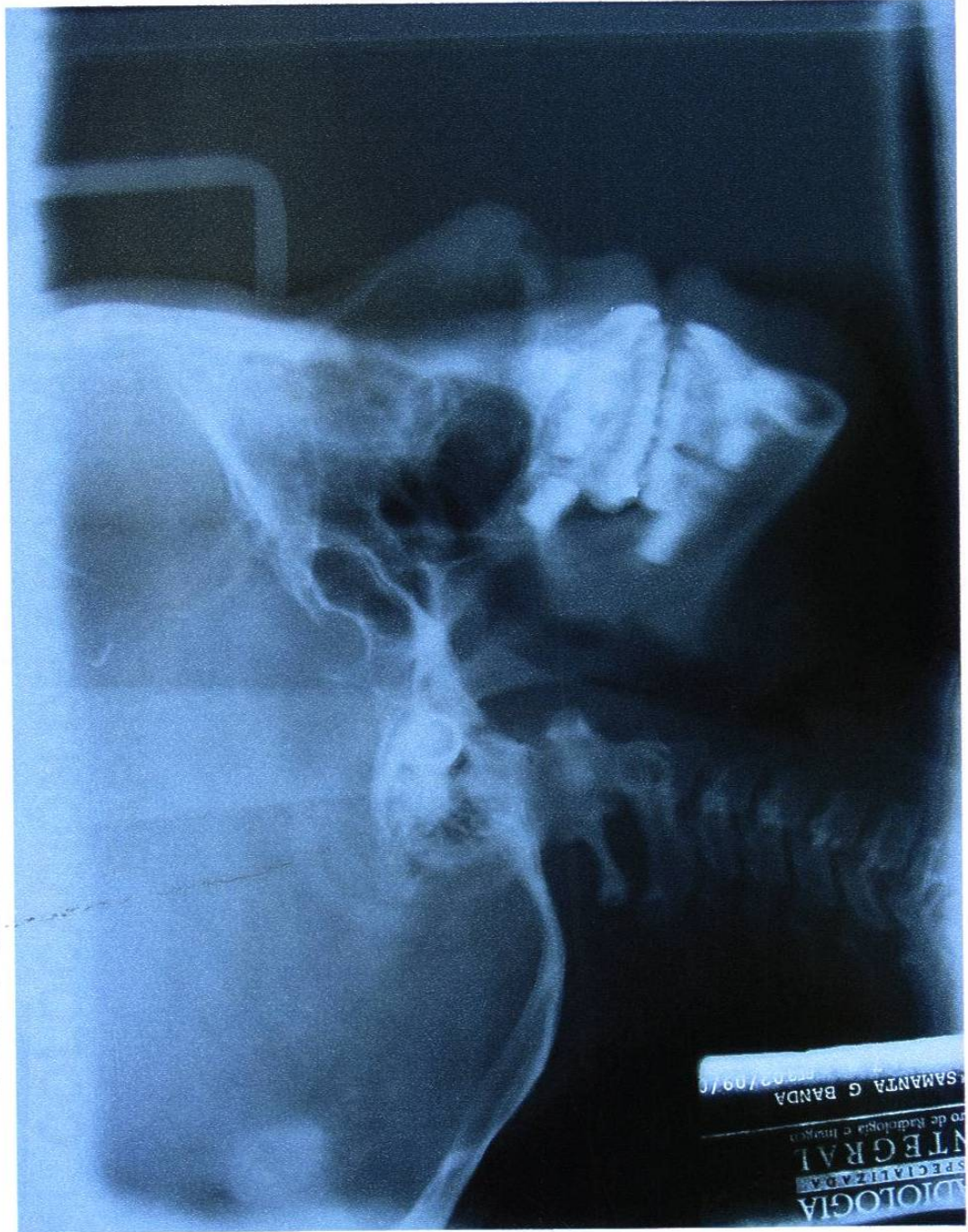
CASO CLÍNICO 1
CEFALOGRAMA LATERAL FINAL



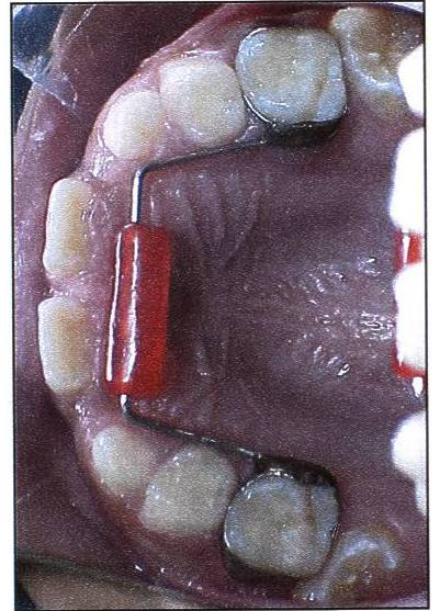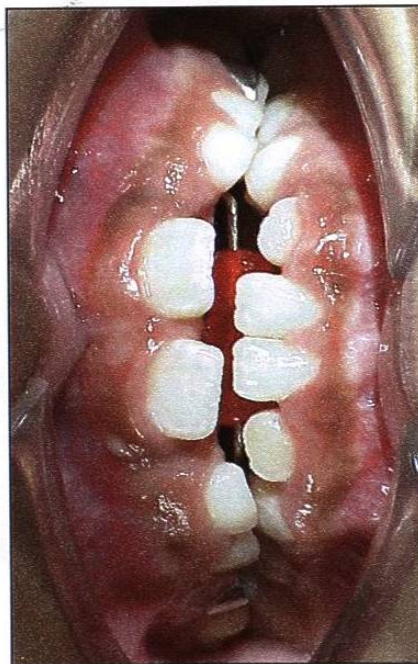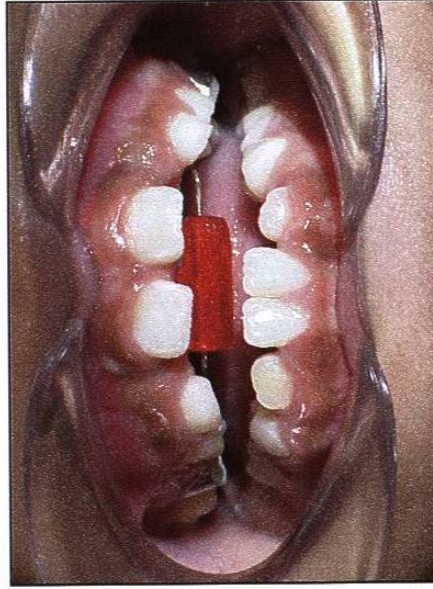
CASO CLÍNICO 2
PRE-TRATAMIENTO DE ARCO PALATINO CON
BARRIL DE ACRÍLICO



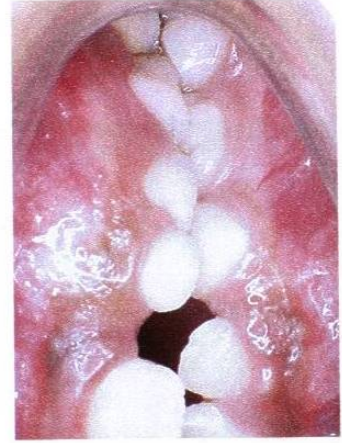
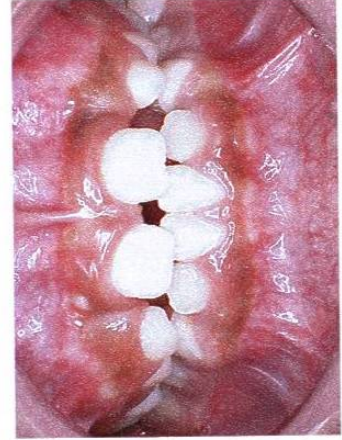
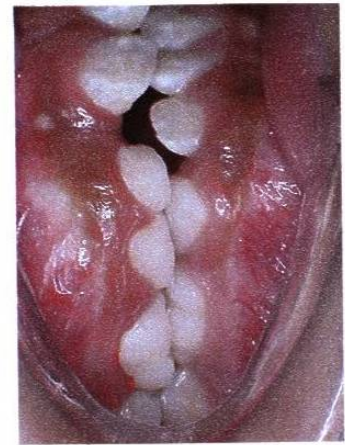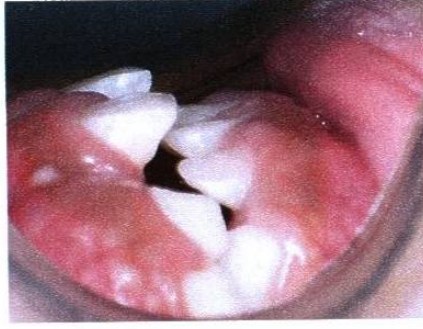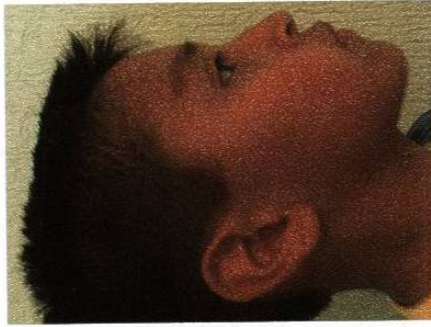CASO CLÍNICO 2
CEFALOGRAMA LATERAL INICIAL



CASO CLÍNICO 2
COLOCACIÓN DE ARCO PALATINO CON
BARRIL DE ACRÍLICO



CASO CLÍNICO 2
POST-TRATAMIENTO DE ARCO PALATINO CON
BARRIL DE ACRÍLICO



CASO CLÍNICO 2
CEFALOGRAMA LATERAL FINAL



